



Title	Orthodontic-Surgical Approach for Treating Skeletal Class III Malocclusion With Severe Maxillary Deficiency in Isolated Cleft Palate
Author(s)	Nakatsugawa, Kohei; Kurosaka, Hiroshi; Mihara, Kiyomi et al.
Citation	Cleft Palate-Craniofacial Journal. 2018, 56(3), p. 400-407
Version Type	AM
URL	https://hdl.handle.net/11094/103600
rights	
Note	

The University of Osaka Institutional Knowledge Archive : OUKA

<https://ir.library.osaka-u.ac.jp/>

The University of Osaka

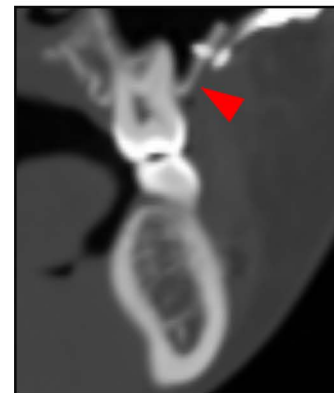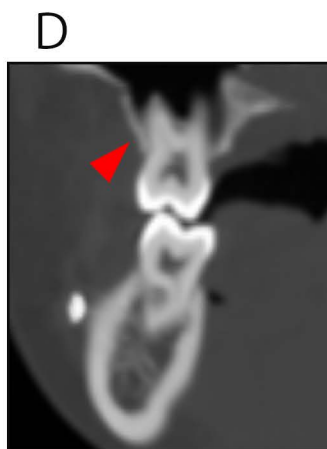
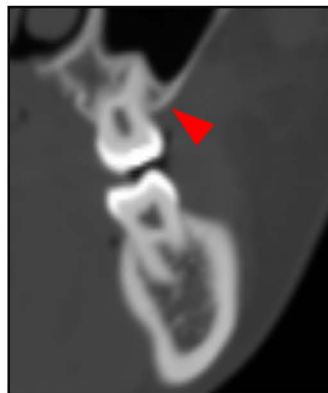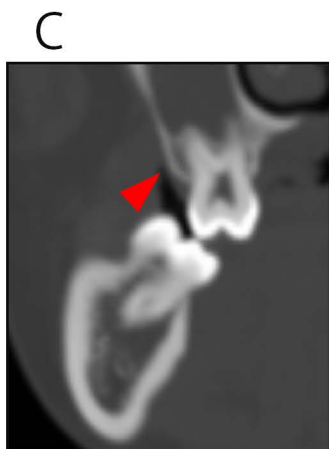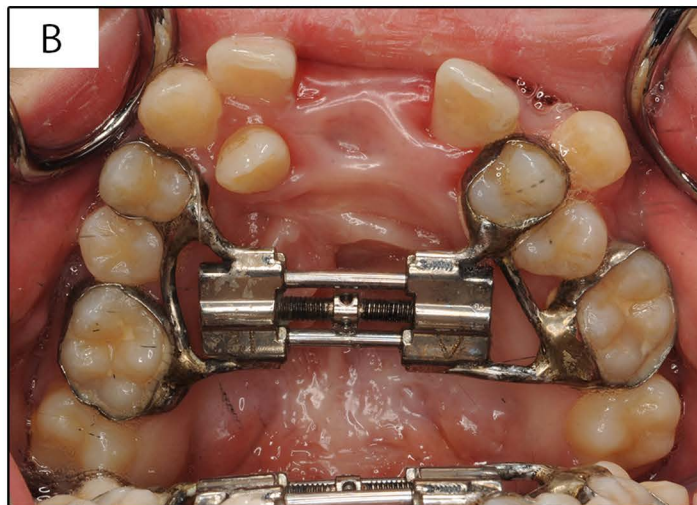
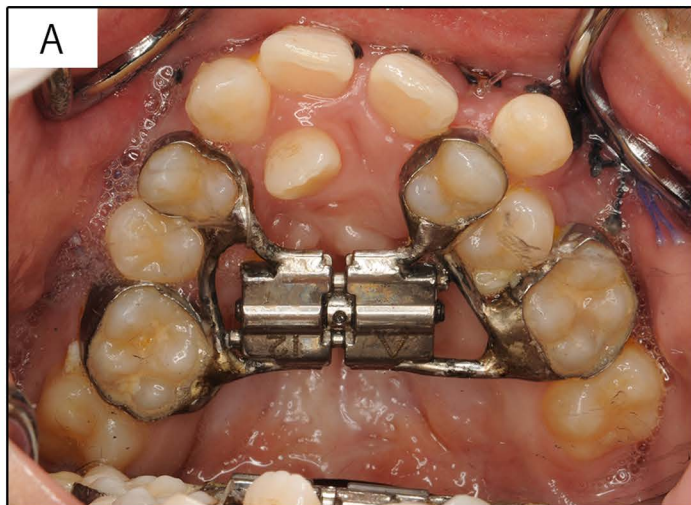


FIGURE 2 Occlusal photographs and three-dimensional reconstructed sliced views of the maxillary first molars of the patient. A: before maxillary expansion. B: after maxillary expansion. C : pretreatment record. D: posttreatment record.

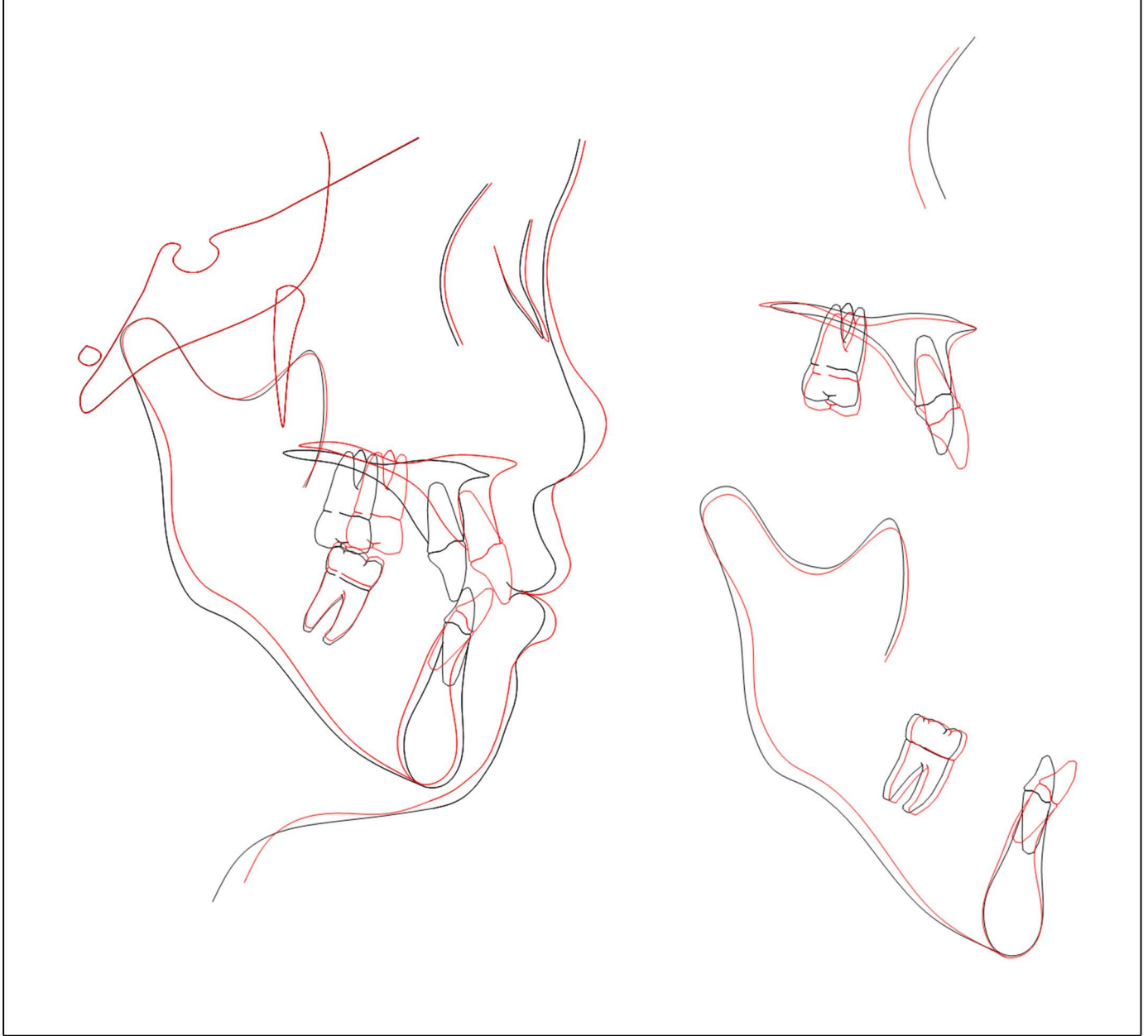


FIGURE 5 Superimposition of pretreatment (black) and posttreatment (red) cephalometric tracings.