Osaka University Knowledge Archive

Title	Roentgenographic features of paraseptal emphysema
Author(s)	曽根, 修輔; 東原, 悳郎; 三浦, 尚 他
Citation	日本医学放射線学会雑誌. 1974, 34(9), p. 651-656
Version Type	VoR
URL	https://hdl.handle.net/11094/14921
rights	
Note	

Osaka University Knowledge Archive : OUKA

https://ir.library.osaka-u.ac.jp/

Osaka University

Roentgenographic features of paraseptal emphysema

Shusuke Sone, Tokuro Higashihara, Takashi Miura, Shizuo Morimoto, and Takeshi Kotake

Department of Radiology, Osaka University Medical School, Osaka
(Director: Prof. Yasushi Shigematsu)

Research Code No.: 506

Key Words: *Lung, Emphysema, Bulla, Air trapping, Pneumothorax*

Paraseptal emphysema のX線所見

大阪大学医学部放射線医学教室
曽根 脩輔　東原 悳郎　三浦 尚
森本 静夫　小竹 武

(昭和49年3月16日受付)
(昭和49年7月22日最終原稿受付)

paraseptal emphysema は気腫性気胞が解剖学的に肋膜直下や肺小葉中隔に沿つて認められるもので，小葉の中心部に気腫のある小葉中心性肺気腫とは対照的なものである．肺門近くの太い気管支や肺血管周囲に認められることもある．気胞を除いた肺は正常といわれており従つて初期には症状はでないし胸部X線検査でもとらえ得ない．進行して自然気胸をおこしたり，大きくなつて単発または多発の Bulla として発見される．

今回報告する2例は胸部X線撮影で偶然に発見された．これによる症状は明らかでなく，1例で行なつた肺機能検査は正常値を示した．X線像は右胸壁直下にこれに沿つて肺尖から腋窩部にかけて約 1.5～2㎝径の多角形に見える Bulla 様の透亮像が並んで認められた．その形と分布が特徴的であると同時に特異な所見として呼吸による形と大きさの変化が認められた．即ち吸気相で膨らみ呼気相で縮小を示した．1例では新月形を示す程に縮小した．ブラは air trapping を示し，これにより次第に増大するし呼気相で縮小しないと記されてきたが，paraseptal emphysema で見られる Bulla は通常のこのような Bulla とは成立機序と機能面で異種としてとりあつかうべきものであろう．Bulla 様の透亮像に隣接する肺はX線的には正常であり瘢痕性変化や気腫性変化を示すものはなく，同側肺は全体として air trapping の所見も示さなかつた．従つて病因的には素因としての肺胞壁の虚弱性を考えるべきであろう．経過をおつて観察し得た第1例はブラは徐々に増大する傾向を示した．一旦生じた Bulla は air trapping がなくても，肺胞内圧の発作性の上昇に対し最も抵抗の弱い場所となるためとみられる．

paraseptal emphysema はその初期には症状はなく肺機能にも影響しないので良性とされているが素因として肺の虚弱性を内蔵していると考えられるのでX線的に認め得ない病変の多発，徐々ではあつても全肺的に進展する危険性をもつと思われる．

Introduction

Paraseptal emphysema is rare. It involves the peripheral parts of the lobules beneath the pleura and along branches of the pulmonary blood vessels.[2)4)5)6)] Edge[2)] reported two cases; its radiological features are the combination of hair-line ring and polygonal shadows located beneath the pleura. Gough[4)] referred to it as a linear emphysema, since bullae are distributed in a line beneath the pleura and along the septa. It is thought that paraseptal emphysema leads to bullous disease or pneumothorax.[6)]

Two cases of paraseptal emphysema were recently encountered at the Medical School Hospital of the Osaka University. In view of the rarity of this condition and the paucity of literature, a further report of its radiographic features seems justified.

Case Reports

Case 1. A. Y., a 44 year old man, had been in good health until the early morning of November 6, 1972, when his train caught fire in the middle of a long tunnel. He was enveloped in smoke for several hours until rescued. On admission in a hospital he had sore throat and shortness of breath. He frequently expectorated sooty sputum. After 24 days in that hospital, he was referred here. Physical examination showed normal breath and normal heart sounds.

The initial postero-anterior chest film showed thin-walled ring shadows mostly 1.5–2.0 cm in diameter just beneath the pleura from the apex to the axillary portion of the right lung. The remainder of the lung was radiologically normal. The diaphragm was neither low nor flat (Fig. 1a and 1a′). Deep expiratory chest film showed normal excursion of the diaphragm. The tomograms of the right lung in full inspiration and expiration showed the ring shadows more clearly and showed dynamic changes: On inspiratory tomograms (Fig. 1b), these thin-walled radiolucent areas were, strictly speaking, rather polygonal in shape and not smooth in their medial aspects. Their upper and lower aspects were margined by fine linear shadows perpendicular to the chest wall. The vascular shadows of the underlying lung were normal. In expiratory tomograms (Fig. 1c and 1c′) bullae were deflated and their size was reduced to one-half of inspiratory phase.

Ventilatory function was normal: Forced expiratory volume was 3710 ml/sec, forced vital capacity 4350 ml, and the ratio FEV$\times$100/FVC, 86%.

Case 2. K. K., a 58 year old man, had had occasional onset of low back pain for the past one year and came to this hospital in August, 1972. A clinical diagnosis of ureterolithiasis was made. The postero-anterior chest film on hospitalization revealed ring shadows adjacent to the chest wall in the 3rd and 4th intercostal spaces of the axillary portion of the right lung. They were about 1.0 cm in diameter. There were scattered punctate calcium deposits in the left lung associated with the obliterated costophrenic sulcus suggestive of healed tuberculosis (Fig. 2a). In inspiratory tomogram radiolucent bullous areas surrounded by marginal atelectatic zone were demonstrated. In expiratory tomogram bullae were deflated and became crescent-shaped radiolucent areas situated parallel to the chest wall. The remainder of the lung showed neither air trapping nor abnormal pulmonary vascular markings (Fig. 2b).

Discussion

Pulmonary emphysema is classified by Reid in two groups based on air-way obstruction.[6)]

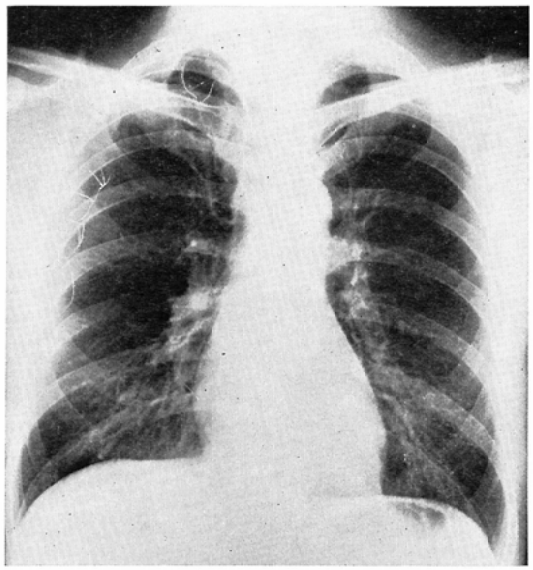

Fig. 1a

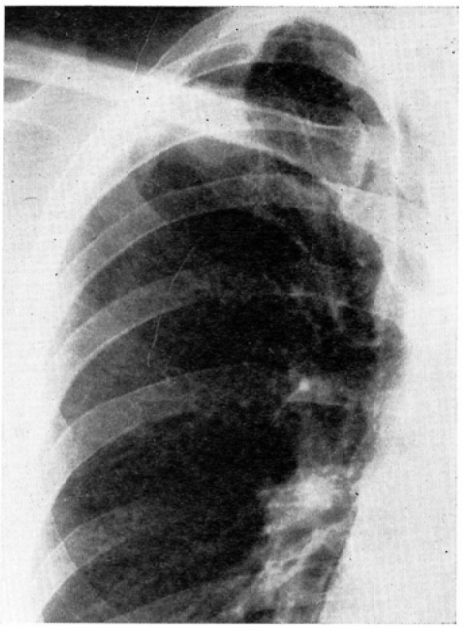

Fig. 1a′

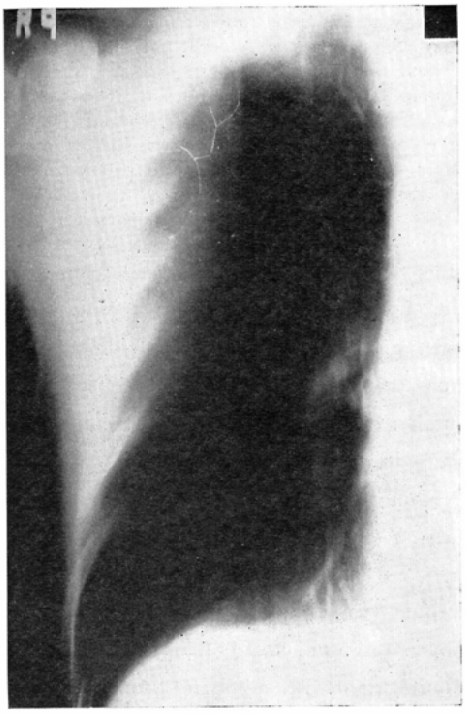

Fig. 1b

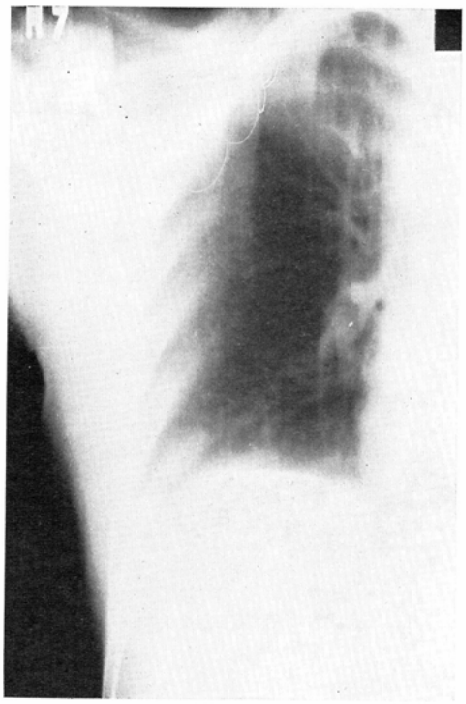

Fig. 1c

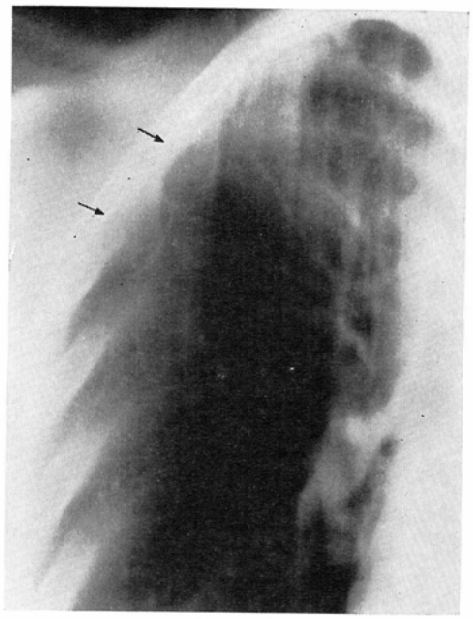

Fig. 1c′

Fig. 1. (a, a′, b, c and c′) Case 1. (a) Posteroanterior chest film reveals several ring shadows (retouched) along the pleura in the apex and axillary portion of the right lung. (a′) Close-up view of the right lung. Polygonal shaped hyperlucent shadows are demarcated on the lung side by inflated hairline and the upper and lower sides by fine lines perpendicular to the lateral chest wall. (b) Tomogram in inspiration. Bullae are retouched. (c) Tomogram in maximal expiration shows slightly deflated bullae with normal diaphragmatic excursion. Bullae are retouched. (c′) Higher magnification of bullae and arrows mark two largest bullae. Since anteroposterior diameter of thorax is reduced to some extent in expiratory phase, expiratory tomographic cut taken slightly posterior to inspiratory cut is shown. (b) and (c) show almost the same layer of the lung as evidenced by the pulmonary vascular markings.

Paraseptal emphysema, together with the aged lung, centri-acinar emphysema, and compensatory emphysema, is included in the emphysema without air trapping. These are considered benign with little disability. Usual roentgen signs of pulmonary emphysema,[3] such as generalized overinflation, air trapping, peripheral vascular deficiency, and redistribution of blood flow in the lung, are not associated. Then paraseptal emphysema may possibly be detected as a single bulla or multiple bullae situated beneath the pleura on a routine chest film or in the case of spontaneous pneumothorax.

In our cases, paraseptal emphysema was diagnosed with roentgen findings suggested by Edge; bullae are typically arranged along the pleura and the underlying lung shows neither overinflation nor parenchymal scars in the vicinity of bullae. Expiratory deflation of bullae shown in this report is contrary to the generally accepted view that bullae trap air during expiration and may undergo an actual increase during expiration as a result of collateral air drift. Expiratory deflation may occur in small bullae which have direct communication with supplying bronchioles. These roentgen features together with the absence of associated past history of chest disease which might have caused bulla formation

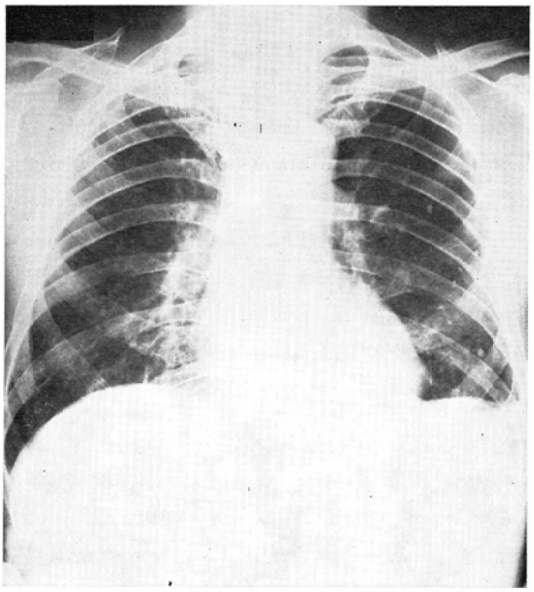

Fig. 1a

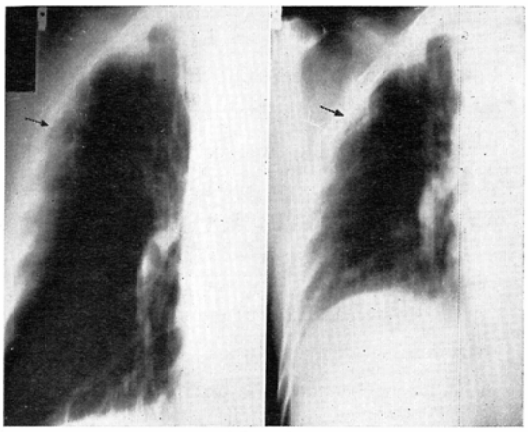

Fig. 1b

Fig. 2. (a and b) Case 2. Posteroanterior chest film reveals hair line shadows in the second anterior intercostal space of the right lung which are suggestive of bullae. (b) Tomogram in inspiration (left) and in expiration (right). Inspiratory tomogram shows several bullae beneath the pleura, one of which is clearly demonstrated, surrounded by the marginal atelectatic zone (arrow), and in expiratory tomogram these bullae are deflated and crescent in shape.

suggest that bullae in paraseptal emphysema are caused by the constitutional weakness of the lung parenchyma.

When located subpleurally, bullae in paraseptal emphysema resemble blebs and the differentiation of these two conditions are not always possible, but a bleb means a collection of air in the deep areolar tissue which lies between the deep elastic layer and the outer elastic layer of the pleura. There is no limitation like septum in the areolar tissue, and the polygonal shape of the hyperlucent areas, the fine linear upper and lower margins perpendicular to the lateral chest wall, which probably consist of connective tissue septa, and the unclearness of the inner aspect are against blebs (Fig. 1a and 1b). Tomographic study is helpful in showing the outline of hyperlucent areas and their relation to visceral pleura (Fig. 2b).

The enlargement of bullae during follow-up roentgen studies has been reported.[1] There is a consistent tendency for the bullous area to enlarge, although the rate of enlargement cannot be predicted. Enlargement of bullae may be caused by air trapping resulting from a check-valve obstruction of supplying bronchioles or by air trapping occuring distal to obstructed bronchioles where aeration is maintained with collateral air drift. It seems inevitable also for bullae without air trapping, as in our cases, more or less to enlarge in the course of time due to occasional attacks of raised intraalveolar pressure, because a less expanding force is required for a bulla to enlarge than normal lung parenchyma.[7] In Case 1, an earlier chest film taken in 1969 was available for study. Careful inspection revealed faint hairline ring-like shadows in the axillary portion of the right lung. There was some en-

largement of bullae during 3 years.

It seems significant to distinguish bullae with air trapping from those without it since these two types of bullae may have different mechanisms in the pathogenesis and different clinical meaning. Paraseptal emphysema represents a typical example of the latter type. In Case 1, heavy exposure to smoke could not be considered as a trigger of bulla formation because no evidence of obstructive bronchiolar changes was shown on the inspiratory and expiratory chest films. It was conceivable, however, that the high intraalveolar pressure caused by severe coughing following inhalation of smoke might be responsible for the enlargement of bullae. Although paraseptal emphysema produces little impairment of lung function and may be regarded as benign, it must be recalled that there is a constitutional weakness in the lung parenchyma as an etiological factor of paraseptal emphysema and this condition may possibly lead to bullous emphysema.

Summary

Roentgen features of paraseptal emphysema were described in two cases. Bullae are demonstrated in normal underlying lung. They are distributed in a line beneath the pleura. Expiratory deflation of bullae is characteristic finding; on inspiratory film they are polygonal shaped and on expiratory film they are crescent shaped. In one case bullae showed some interval enlargement and ventilatory function studies showed no impairment.

Acknowledgements

We wish to express our thanks to Associate Professor Takahiro Kozuka, Department of Radiology, Osaka University Medical School, for review of the manuscript.

References

1) Boushy, S.F., Kohen, R., Billing, D.M., and Heiman, M.J.: Bullous emphysema: clinical, roentgenologic and physiologic study of 49 patients. Dis. Chest, 54: 1968, 327–334.
2) Edge, J., Simon, G., and Reid, L.: Peri-acinar (paraseptal) emphysema: its clinical, radiological, and physiological features. Brit. J. Dis. Chest, 60: 1966, 10–18.
3) Fraser, R.G., and Peter Pare, J.A.: Diagnosis of Diseases of Chest. pp 999, 1002–1008, 1024–1032. W.B. Saunders Company, Philadelphia, 1970.
4) Gough, J.: The pathogenesis of emphysema. In: A.A. Liebow, and D.E. Smith (eds.), The Lung. pp 109–133. Wiliams & Wilkins Company, Baltimore, 1968.
5) Heard, B.E. and Izukawa, T.: Pulmonary emphysema in fifty consecutive male necropsies in London. J. Pathol. Bacteriol. 88: 1964, 423–431.
6) Reid, L.: Emphysema: classification and clinical significance. Brit. J. Dis. Chest. 60: 1966, 57–65.
7) Spencer, H.: Pathology of the Lung. 2nd Ed., pp 519–526. Pergamon Press, Oxford, 1968.