Osaka University Knowledge Archive

Title	Effect of Ionizing Radiation on Tumor Immunity I. Effect of radiation on immunity against homologous and heterologous transplantation of tumor
Author(s)	戸部, 龍夫; 新部, 英男; 鰀目, 一郎 他
Citation	日本医学放射線学会雑誌. 1968, 28(2), p. 150-159
Version Type	VoR
URL	https://hdl.handle.net/11094/14928
rights	
Note	

Osaka University Knowledge Archive : OUKA

https://ir.library.osaka-u.ac.jp/

Osaka University

Effect of Ionizing Radiation on Tumor Immunity
I. Effect of radiation on immunity against homologous and heterologous transplantation of tumor

Tatsuo Tobe, Hideo Niibe, Ichiro Yonome, and Nobuo Koike
Department of Radiology, School of Medicine, Gunma University
(Director: Porf Tobe Tatsuo)
Takashi Okonogi
Central Research Laboratories, Sankyo Co., Ltd.

腫瘍免疫におよぼす電離放射線の影響
第1報 同種および異種移植免疫に対する照射の影響

群馬大学医学部放射線医学教室（主任：戸部龍夫教授）
戸部龍夫 新部英男
鰒目一郎 小池脩夫
三共中央研究所病理部
小此木 丘

（昭和42年9月11日受付）

腫瘍免疫の存在を肯定する立場からすれば，腫瘍の放射線療法に際しては免疫機構の障害を一考する必要があろう．

我々は，先づ，基礎的実験の第1歩として明らかに同種移植免疫の成立する吉田肉腫—Wistar系 Rats を用いて，免疫ラットを作り，獲得した抗移植性に対するX線全身照射の影響を，吉田肉腫の異種移植時にみられる先天的抗移植性と対比しつつ検討を加えた．

ラットの免疫は，Proteus mirabilis 処理または，細胞毒であるTMTD処理によつて吉田肉腫の皮下移植腫瘍を治癒，消失せしめることによつて獲得せしめた．Proteus mirabilis または，TMTD処理で治癒した Rats は，吉田肉腫細胞10^7コの再移植を腹腔内にうけても，完全に排除しうる抗移植性を獲得した．ここに獲得した抗移植性は，100日以上持続した．

500R全身照射をうけた免疫 Rats は，照射後2日以降において完全に抗移植性を失い，照射後25日でも抗移植性の回復はみられない．しかし，照射後9日以降に吉田肉腫細胞を再移植された場合には，腫瘍の一過性増殖後，抗移植性を再び獲得し治癒するものもある．このことは，一見，抗移植性の回復とも理解できるが，抗移植性の発現が再移植後7日以後に認められることから，抗原としての吉田肉腫細胞が注入されたことによつて，新ためて抗移植性を獲得したものであろう．Mice に対する吉田肉腫の異種移植は，一過性増殖をしたのち全例自然治癒したが，500R全身照射をうけたのち2日目に移植された場合には，平均生存日数10日で全例腫瘍死した．

以上，Rat における後天的抗移植性および Mice における先天的抗移植性ともに，500R全身照射後2日前後において抗移植性の消失をみてお

り，放射線感受性から考え，抗体産生系は，Rat でも Mouse でも同一系統の組織系であると考えられる．即ち，脾，リンパ組織などが考えられるが，この点については，次報で報告する．

There are various opinions concerning immunity against human caner. The presence of immunity against auto-tumor in animal was made clear by Takeda[1], Klein[2], and Czajkowski[3] thanks to their excellent experimental technics. Also with regard to human cancer there are reports[4] on cases of long survival or spontaneous cure despite imperfect therapy. It is therefore certain that also human subjects can have immunity against cancer. Difficulty in immunological therapy for human cancer can be considered to lie in that human cancer cells, which belongs to LAT of the HML classification by Takeda et al[5], may have weak antigenicity, that is, low antibody titer.

Now there are two opposite trends in the study of radiation effect on immunity: The first aims to elevate antigenicity of tumor cells by irradiation. There are in effect reports[6] of cases which were spontaneously cured by imperfect radiation therapy. Finney et al[7] observed elevation of anti-tumor antibody titer by irradiating human cancer. Furthermore, Taruzawa[8] demonstrated by serological technic that cells of the normal organ, which has no antigenicity, acquired it as the result of irradiation, thus establishing autoimmunity. Namely, radiation is considered, according to this view, to give positive aid to immunological therapy.

The second assumes by contrast that radiation blocks the immune mechanism, especially the antibody producing system. That radiation impedes antibody production was first reported in 1908 by Benjamin and Sluka, and since then replications have been made by many workers. And the results were systematized by W.H. Taliaferro[9].

If immunity against cancer is really present, there is possibility that control of cancer may conversely become difficult as the result of inadequate radiation therapy.

In effect, when Wistar rats, on the 7th day after subcutaneous transplantation of Yoshida sarcoma, were irradiated with 500R on the whole body inclusive of the tumor, it was enlarged as compared with that in non-irradiated controls, and the host animals died early from the tumor (Fig. 1). It can therefore be considered that the irradiation may have damaged the tumor cells on the one hand, but abolished immunity on the other. It is of great interest whether the same, putting aside the extent, would occur in the human subjects.

As the first step of the basic experiments on this problem, we prepared immune animals by Yoshida sarcoma- Wistar rats combination, which is known to establish homologous transplantation immunity, and compared the effect of X-ray irradiation on this acquired immunity with that on the congenital one in heterotransplantation.

Immune rats were obtained by curing the subcutaneously transplanted Yoshida sarcoma with proteus mirabilis or TMTD, a cytotoxin (Fig. 2). Antitumor action of proteus mirabilis against Ehrlich cancer has already been reported by Murata et al[10] and by Okonogi and Nakahara[11].

Materials and Methods

Animals: Male Wistar rats, weighing about 120 g, and male dd mice, bred by sister-brother mating in the Animal Laboratory of School of Medicine, Gunma University, weighing about 25 g, were used.

Tumor: Yoshida sarcoma (Y.S.), supplied by Sasaki Laboratory and transplanted through generations in this department, was used.

Fig. 1 Effect of Whole Body X-Irra Biation on Tumor Bearing Rats

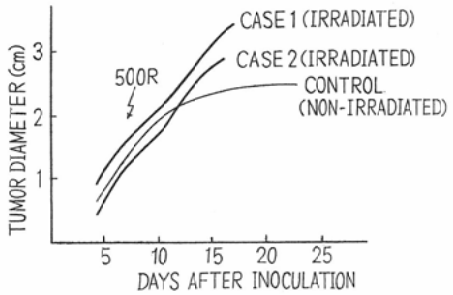

Fig. 2 TMTD (Tetramethylthiuram-disulfide)

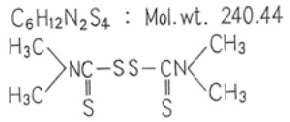

TMTD: To 1g of TMTD of Kawaguchi Chem. Ind. Co. was added 0.2 g of CMC, and after mixing and grinding well in a mortar, 20 ml of saline solution was added to the mixture to prepare a dispersion.

Proteus mirabilis: Proteus mirabilis cultured and frozen and dried in the Central Research Laboratories of Sankyo Co. were dissolved in saline solution when used.

Immunization of rats: Rats were subcutaneously inoculated with 10^6/0.1 ml of Y.S. cells on the back, and some of them received 15 mg/0.3 ml of TMTD 7 days later, injected from three directions into the tumor, which consequently disappeared after 2 weeks, others intravenously received 10^5–10^7/0.2 ml of the live organisms or 5 mg/0.2 ml of the killed one (wet weight) on the 4th or 7th day after the tumor cell inoculation, and the tumor disappeared 2 weeks thereafter. To observe change in the tumor after treatment with TMTD and proteus, the animals were sacrificed from time to time for histopathological observation.

Irradiation and retransplantation to the immune rats:

(1) The immune rats were irradiated at 500R on the whole body, and on days 0, 2, 5, 9, 14, and 25, they received intraperitoneally each 10^7 Y.S. cells. On days 1, 2, 4, 6, 9 and 14 thereafter, ascites were drawn to observe proliferation of the tumor cells, and those which died meantime were autopsied. Those which survived were killed for autopsy at 60 days after the transplantation.

(2) On days 0 and 2 after whole body irradiation at 200R, the same procedure as described above was followed.

Pre-irradiation and heterotransplantation to mice:

On days 0 and 2 after whole body irradiation at 200 and 500R, mice were intraperitoneally inoculated with 10^7 of Y.S. cells, and the same observations were made as after the retransplantation to the immune rats.

Irradiation: With the Toshiba's K X C—18 type. 150 kvp, 25 mA, 0.5 Cu + 0.5 Al, 0.83 mm Cu, 10 × 10 cm², 30 cm, 114R/min.

Histological observation: (1) Ascitic cells were smeared on the slide glass, and either fixed with methanol and stained with Giemsa or fixed with Carnoy and stained with PAS.

(2) The tissue block was fixed with formalin, embedded with paraffine and sectioned, and then stained by H.E., Mallory, PAP silver impregnation or PAS. When necessary, staining for the organism was also made.

Results

The subcutaneous transplantation of the tumor cells was judged as successful, when the tumor attained

10 mm and above in the average for three diameters. It was successful in 348 of 352 animals, that is 98.8%.

1. Treatment of the subcutaneous tumor.

When the tumor disappeared within 2 weeks after TMTD or Proteus mirabilis treatment, it was judged as cured. As shown in Table 1, the topical TMTD group showed the highest curability, 78%, and the live proteus mirabilis group 53%, both being conspicuously different from 6% for non-treated controls.

Table 1 RESULTS OF TREATMENT FOR TUMOR-BEARING RATS

TREATMENT	NO. OF RATS	NO. OF CURE	CURE RATE
T. M. T. D.	69	54	78%
PROTEUS M. (LIVE)	93	49	53
PROTEUS M. (KILLED)	24	8	24
UNTREATED	50	3	6

a) TMTD treatment

Cured cases: The tumor grew, as in non-treated cases, for several days after topical TMTD injection. At about 10 days, however, growth of the tumor stopped. Thereafter, it regressed either passing the course of ulceration on the skin and subsequent cicatrization, or without this course.

Histologically, there were in the early stage, at the site of TMTD injection, degeneration and necrosis of the tumor cells, and among the degenerated cells, was seen pale H.E. stained substance, which was considered to be TMTD. But those cells which were not in contact with TMTD showed brisk proliferation istead of degeneration (Plate 1). At about 10 days after TMTD treatment, however, the tumor cells abruptly underwent degeneration, and were replaced by fibrous tissue, thus presenting a picture of cicatrical healing.

Uncured cases: Out of 69 treated cases, 15 were uncured, and out of these 15, 11 died within 10 days after TMTD injection. Autopsy revealed these deaths to be due to TMTD intoxication. The remaining 4 cases died of the tumor, which remained without regression.

b) Proteus mirabilis treatment

Cured cases: In 1–5 days after intravenous injection of proteus mirabilis into the tail vein, the tumor stopped its growth, and was gradually resolved and lost.

Histologically, the majority of the tumor cells underwent coagulation necrosis within 3 days after the treatment, and the necrotic focus was surrounded by neutrophil infiltration, which was further encircled by fibrous tissue. Between the necrotic focus and neutrophil infiltration, were seen colonies of proteus mirabilis (Plates 2-a, b). Some of the tumor cells were resolved without forming coagulationnecrotic focus.

Difierence between the live and the killed proteus mirabilis treated group was that no case of the latter showed coagulation necrosis.

Uncured cases: A small number of cases died within several days after intravenous injection of the bacterial cells. The majority exhibited scarcely any difference from non-treated rats, with the tumor being enlarged.

2. Irradiation to immune rats

A) Mortality rate

Table 2 shows the results of intraperitoneal retransplantation of Y.S. cells in rats in which the subcutaneous tumor was lost by TMTD or proteus mirabilis treatment. In all the 48 cases, the transplanted tumor was kept rejected, as late as 100 days after the cure at the longest. Whole body irradiation at 200R did not produce any marked effect on the transplantation immunity, but at 500R, it gave rise to death from the retransplanted tumor. Mortality rate varied depending on the interval between the irradiaion and the retransplantation. The rate was only 25% when the retransplantation was made immediately after the irradiation, but it was above 90%, indicating the abolishment of immunity, when the interval was 2 and 5 days. When, however, the interval was above 9 days, the rate was again lowered.

Table 2 EFFECT OF X-IRRADIATION ON TRANSPLANTED TUMOR IMMUNITY

DOSE	DAYS AFTER IRRADIATION	NO. OF RATS	NO. OF DEATH	DEATH RATE%
(R)	0	12	3	25
	2	15	14	93
	5	11	10	90
500	9	9	5	56
	14	14	11	79
	25	5	4	80
200	0	6	0	0
	2	6	0	0
0	—	48	0	0
UN-TREATED	—	225	225	100

B) Findings in ascitic fluid.

a) Healthy control rats

Until 2 days after the tumor transplantation, reactive cells such as monocytes, granulocytes and lymphocytes were slightly seen in the abdominal cavity, with marked proliferation of the tumor cells. On 4 days, the reactive cells almost disappeared, and the tumor cells showed such proliferation as if in "pure culture". (The tumor cells are contained 95% or more within the ascitic fluid cells). After 6 days, not only bleeding but also icterus was observed, and although some of the tumor cells exhibited a degenerative picture, all the host animals died of the tumor in about 8 days.

b) Non-irradiated cured rats

Reactive cells appeared immediately after the retransplantation, and the tumor cells, having scarcely any chance of proliferation, underwent degeneration after several days, and were completely romoved from the abdominal cavity.

c) After 200R irradiation

In the early stage after the retransplantation, slight proliferation of the tumor cells was observed. But there was strong infiltration of reactive cells, especially mononuclear cells, and on 9 days after the retransplantation, no tumor cell was visible intraperitoneally.

d) After 500R irradiation

Retransplantation immediately after irradiation:

As early as 2 days after the transplantation considerably strong reactive cells appeared, and proliferation of the tumor cells was inhibited. On 4 days, proliferation of the tumor cells was invisible in the majority of cases, but in 3 cases, many tumor cells showed mitotic figure. On 6 days, these 3 cases manifested remarkable proliferation of the tumor cells, "pure culture", and on 14 days all of them died. The other 9 cases survived without showing any marked proliferation of the tumor cells.

Retransplantation on 2 days after irradiation:

Out of 15 cases, 11 died of the tumor after running a similar course to that after the transplantation to healthy rats. The other 4 cases markedly showed reactive cells, that is, inhibition of the tumor cell growth, until 4 days, but on 6 days, 3 of them exhibited tumor cell proliferation in "pure culture" and eventually died of the tumor (Plate 3). Only 1 survived without showing any proliferation of the tumor cells.

Transplantation on 5 days after irradiation:

Only 1 of 11 cases showed anti-tumor immunity, rejecting the tumor cells, but in the other 10 cases marked proliferation of the tumor cells was visible from the beginning, and the host animals died of the tumor after running a similar course to that of healthy rats after the transplantation.

Retransplantation on days 9, 14 and 25 after irradiation:

In the early stage after the retransplantation, there was marked proliferation of the tumor cells, indicating the absence of the transplantation immunity. On 4 days, all the cases showed tumor cell proliferation in "pure culture". On 6 days, however, degenerative tendency was found in the tumor cells, and on 9 days, degeneration and destruction became remarkable in some. On 14 days the tumor cells disappeared completely, and the cure was realized spontaneously.

3. Effect of irradiation on transplantation immunity in mice

a) Non-irradiated group

Until 4 days after the transplantation, Y.S. cells were proliferated in the abdominal cavity in "pure culture". Later, however, their rapid degeneration and destruction took place together with appearance of reactive cells, and all were cured spontaneously.

b) After 200R irradiation

Time necessary for the rejection of the tumor cells was 1–2 days longer than for the non-irradiated group, but none died of the tumor.

c) After 500 R irradiation

Transplantation immediately after irradiation:

Numerous tumor cells were intraperitoneally visible until 6 days after the transplantation, but on 9 days, their degeneration and destruction were remarkable, and all the cases were prevented from dying of the tumor.

Transplantation on 2 days after irradiation:

Proliferation of the tumor cells was as brisk as in the same cases of rat, and there was poor appearance of reactive cells. Marked deposition of ascitic fluid was observed (Plate 4). All the host animals died on 8-12 days after the transplantation, with an average survival of 10 days (Table 3).

Discussion

When Y.S., subcutaneously transplanted to rats was treated with TMTD or proteus mirabilis, it was cured at high rate. And all the cured cases demonstrated resistance to the intraperitoneal retransplantation of Y.S.

Table 3 EFFECT OF X-IRRADIATION ON HETEROLOGOUS TRANSPLANTABILITY

DOSE	DAYS POST-IRRAD	NO. OF MICE	NO. OF DEATH	DEATH RATE	SURVIVAL TIME
500 R	0	8	0	0 %	DAYS
	2	16	16	100	10.0
200 R	0	8	0	0	—
	2	8	0	0	—
0 R	—	16	0	0	—

TMTD is used as a vulcanization accelerator in rubber industry and also as an agricultural medicine on account of its anti-bactrial and antifungal action. It is a strong cytotoxin to vertebrate tissue, which undergoes softening and lysis when brought to contact with it. As to the mechanism of cure of subcutaneous tumor by TMTD, three possibilities can be considered: A first is its direct action on the tumor causing degeneration, necrosis and lysis of the tumor cells. A second is its action on the basal part of tumor, giving rise to circulatory disorder, and secondarily producing coagulation necrosis of the tumor cells. And a third is potentiation of immunity, bringing about cure indirectly by increasing the resistance of the host.

When TMTD was injected into tumor tissue, lysis was produced several hours later. It is therefore assumable that TMTD exerts direct action on the tumor cells. Also in in vitro experiment, effect of TMTD on Y.S. was demonstrated immediately after mixing of these two by evident inhibition of anaerobic glycolysis[12].

It took, however, about 10 days to block the proliferation of the tumor by TMTD injection. Therefore, direct action of TMTD alone can not be considered responsible for the cessation of proliferation and regression of the tumor. In effect regression was not produced at all when host animals were irradiated with 500 R, with the tumor part covered with lead, immediately before or 5 days after TMTD treatment; as seen in Fig. 3, all the animals died in this experiment within 24 days after the transplantation. This seems to indicate that when the antibody producing system is destroyed by irradiation, regression of the tumor is not obtained by TMTD treatment. And this gives support not to the second but to the third possibility that TMTD may bring about cure by enhancing the resistance of the host. And the fact that TMTD, injected into the extra-tumor tissue, failed to produce any cure permit us to consider that this agent must have produced regression on the tumor secondarily by giving rise to specific immunological reaction to the tumor, and not by unspecific general reaction. In this respect, the mechanism of TMTD action seems to be the same with that of the potentiated immunization by ligation and release method, which was reported by Takeda et al[13].

Fig. 3 Effect of Tmtd-Therapy for Tumor Bearing Rats Irradiated

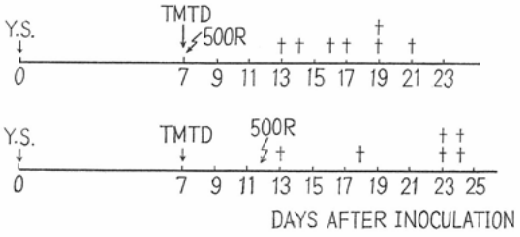

Plate 1 Tumor cells in contact with TMTD show degeneration and necrosis. H.E. stain

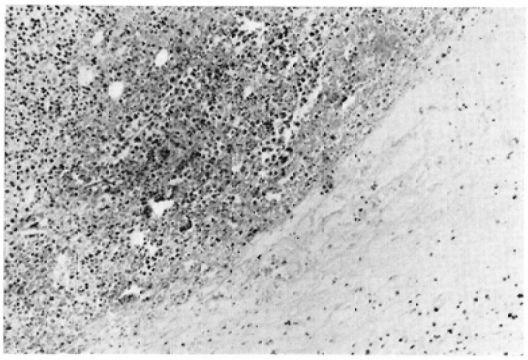

Plate 2-a On 3 days after the live Proteus mirabilis treatment, the majority of the tumor tissue undergo coagulation necrosis and are surrounded by neutrophil infiltration and fibrous tissue. H.E. stain

Plate 2-b Colonies of Proteus mirabilis are seen. H.E. stain

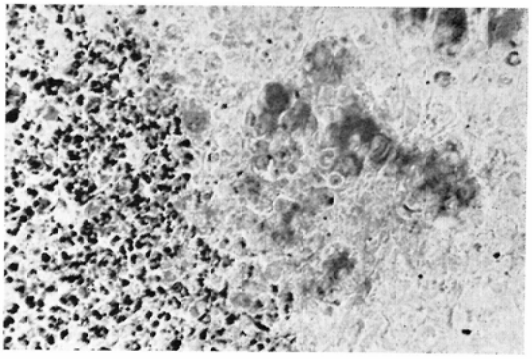

Plate 3 The immune rat intraperitoneally retransplanted after whole body irradiation with 500 R shows tumorous ascites and tumorforming in the abdominal cavity.

Plate 4 The upper is one of the nonirradiated group, the lower is irradiated before the transplantation.

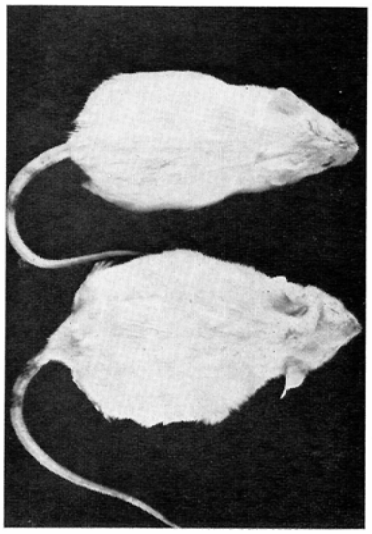

It was already reported by Okonogi and Nakahara that proteus mirabilis was highly effective (histologically 100% effective) against Ehrlich's solid tumor. It is considered that an approximately same mechanism may underlie its actions on subcutaneous Y.S. in rats and on Ehrlich's cancer in mice. But the former was cured at lower rate by this organism, and, different from the latter, it was in many cases softened and resolved without undergoing coagulation necrosis. Okonogi et al. explained the action mechanism of proteus mirabilis by saying that it produces coagulation necrosis through damaging blood vessel in the tumor tissue. The cure rate by proteus mirabilis in the present experiment was higher than in the early stage results in Ehrlich's solid tumor, reported by Murata et al. This occurred probably because Murata et al assessed the effect macroscopically, and did not included, as cured, those in which the tumor underwent coagulation necrosis, but nevertheless was not yet resolved.

Curability by proteus mirabilis administration was lower than that by TMTD treatment. However, the latter, which is a cytotoxin exerting its direct action on the tumor cells, can not be applied systemicly, whereas the latter, whose direct action on the tumor cells is not yet known for the moment, can be used systemicly for the treatment of the subcutaneous tumor.

Rats cured either with TMTD or with proteus mirabilis manifested perfect resistance to intraperitoneal transplantation of Y.S., although there may be difference between their action mechanisms. And the resitance persisted as long as 100 days after the cure.

Effect of radiation on immune rats was evidently visible on 2 days and later following 500 R irradiation. Also in heterotransplantation of Y.S. into mice, the hosts died without rejecting or preventing the proliferation of the tumor cells when the transplantation was made on 2 days after 500 R irradiation, showing agreement between the two cases.

Effect of radiation on mice can be explained as inhibition[14)15)16)] of antibody production against Y.S.. But effect of radiation on rats can not be interpreted simply as inhibition of antibody production, because ascites smear samples prepared immediately after the retransplantation revealed that the strong anti-tumor immunity which had already been acquired before irradiation was abolished together. And this lost immunity could not be recovered as late as 25 days after irradiation.

In the group of the retransplantation on 9 days and later following the irradiation, some were cured, probably as the result of new antibody production against the retransplantation. This is a fact of interest considering that when non-treated healthy control rats received transplantation of the tumor, no cases were cured spontaneously. It is assumed that though the whole body irradiation with 500 R may completely abolish the acquired transplantation immunity, it nevertheless may leave behind some anamnesis, which will prompt antibody production against the second transplantation at higher speed than against the first, thus bringing about the cure. The above mentioned interval of 9 days or more will mean the time necessary for the recovery of the antibody productivity from the damage given by 500 R whole body irradiation. And the fact that one same group contained both cured and tumor-dying cases may indicate that the time necessary for antibody production against the retransplantation and that necessary for proliferation of the retransplanted tumor cells to cause the death of the hosts may approximately be identical. Of course histocompatibility antigen, especially R antigen by Aizawa et al[17)] may have to be considered. However, since all the cases died in the present experiment when 10 of Y.S. cells were intraperitoneally transplanted without any preliminary treatment, participation of R antigen is assumed insignificant. It seems that the abolishment of the transplantation immunity by 500 R irradiation in the present experi-

ment may not indicate the damage of the antibody molecule, but mean that the principal role in the transplantation immunity is played by cellular antibody and not by serum antibody.

That the abolishment of the transplantation immunity and that of antibody productivity in heterotransplantation both occurred likewise on 2 days after 500 R irradiation may have resulted from the identity of the organ or cell system which was damaged. This point will further be investigated.

Summary

Wistar strain rats which received subcutaneous transplantation of Yoshida sarcoma were cured at high rates with TMTD or Proteus mirabilis, and at the same time they acquired transplantation immunity to resist completely the retransplantation of 10^7 Yoshida sarcoma cells. This acquired immunity persisted more than 100 days.

When these immunized rats received 500 R whole body irradiation, the immunity was perfectly lost on 2 days after the irradiation, and was not restored as late as 25 days. When, however, Yoshida sarcoma cells were retransplanted on 9 days or more after the irradiation, the immunity was reacquired by some of them, bringing about the cure.

When mice received heterotransplantation of Yoshida sarcoma, all were cured despite transient proliferation of the tumor cells. But when the transplantation was made on 2 days after 500 R whole body irradiation, all the cases died of the tumor.

It was consequently assumed that considering the radiosensitivity, the antibody production system may be tissue or cells whose function is abolished about 2 days after the whole body irradiation in a dose of 500 R, and restored after 9 days or more.

Acknowledgement

The authers wish to express their thanks to Mr. Katsuyama and Mr. Hosono for technical assistance.

References

1) Takeda, K., Aizawa, M., et al. Tr. Soc. Path. Jap., 53: 136–137, 1964.
2) Klein, G., Sjogren, H.O., Klein, E., and Hellstrom, K.E. Cancer Research, 20: 1561–1572, 1960.
3) Czajkowski, N.P., et al. Cancer, 19(6): 739–749, 1966.
4) Everson, T.C., and Cole, W.H., Ann. Surg., 144: 366–383, 1956.
5) Takeda, K., Kikuchi, U., Yamawaki, S., Aizawa, M., and Nakamura, K., Jap. J. Clin. Med., 24: 134–145, 1966.
6) Stewart, F.W., Texas Rep. Biol. and Med., 10: 239–253, 1952.
7) Finney, J.W., Byers, E.H., and Wilson, R.H., Cancer Res., 20: 351–356, 1960.
8) Tarugawa, S., Nipp. Act Radiol., 17(12): 466–497, 1957.
9) Taliaferro, W.H., Ann. N.Y. Acad. Sci., 69: 745–764, 1957.
10) Murata, T., et al. Life Schiences, 4(10): 1055–1067, 1965.
11) Okonogi, T. and Nakahara M., Jap. J. Bact., 21(4): 249, 1966.
12) Tobe, T. et al., unpublished.
13) Takeda, K., Aizawa, M., Tuji, U., and Nakamura, K., Proceedings of the Japanese Cancer Association The 23th Annual Meeting, 299–300, 1964.
14) Toolan, H.W., Proc. Soc. Exper. Biol. and Med., 77: 572–578, 1951.
15) Taliaferro, W.H., Taliaferro, and Jaroslow, B.N., Radiation and Immune Mechanisms, 17–30, Academic Press 1964.
16) Salivin, S.B. and Smith, K.F., J. Exptl. Med., 109: 325–338, 1959.
17) Aizawa, M., Itakura, K., Katagili, H., and Nakamura, K., Journal of Cancer Immunopathology, 2: 131–137, 1966.
18) Hollingoworth, J.W., Proc. Soc. Exptl. Biol. Med., 75: 477–479, 1950.
19) Kohn, H.I., J. Immunol., 66: 525–533, 1951.
20) Perkins, E.H. and Marcus, S., J. Infect. Diseases, 102: 81–87, 1958.