The University of Osaka
Institutional Knowledge Archive

Title	Tumor tissue structure and radiosensitivity II. Mammary cancer in C3H/He.Ms. strain mice
Author(s)	新部, 英男; 戸部, 龍夫; 小池, 脩夫 他
Citation	日本医学放射線学会雑誌. 1969, 28(10), p. 1341-1349
Version Type	VoR
URL	https://hdl.handle.net/11094/16683
rights	
Note	

The University of Osaka Institutional Knowledge Archive : OUKA

https://ir.library.osaka-u.ac.jp/

The University of Osaka

Tumor Tissue Structure and Radiosensitivity
II. Mammary cancer in C_3H/He.Ms. strain mice

Hideo Niibe, Tatsuo Tobe, Nobuo Koike and Kohji Sakaino
Department of Radiology, School of Medicine, Gunma University
(Director: Prof. T. Tobe)

腫瘍組織構築と放射線感受性
II. C_3H/He.Ms 系マウスの乳癌について

群馬大学医学部放射線医学教室（主任：戸部竜夫教授）
新部 英男　戸部 龍夫　小池 脩夫　境野 宏治

（昭和43年3月7日受付）

C_3H/He.Ms. 系マウスに自然発生した乳癌の同系マウスの大腿筋肉内初代移植腫瘍を用い，腺癌の組織構築と放射線感受性について放射線病理学的に検索を試みた．

本実験に用いた腫瘍の組織像は，大部分が類円形の核をもつた骰子形ないしは円柱形の細胞の充実増殖からなつており，一部に腺腔形成を伴う比較的分化傾向の低い腺癌であつた．組織模倣性に乏しく単純癌様に充実性増殖を示す部分の腫瘍細胞は，増殖力が旺盛であり，かつ，放射線感受性も高いこと，一方，腺様構造をとり分化傾向を示す部分の腫瘍細胞は，増殖力が低く，かつ，感受性も低いことが認められた．前報の吉田肉腫やMC-誘発肉腫を用いての実験でも，腫瘍の増殖力と放射線感受性とに相関があること，さらに，この関係は腫瘍組織内の血管からの距離によつて決定されることを報告した．しかし，C_3H/He.Ms 系マウスに発生した乳癌では，血管との距離によつて腫瘍の増殖力が決定されるとは限らず，むしろ，腫瘍細胞の分化が増殖力を支配し，かつ，感受性を決定づける主役を演じてるものであることを示唆する所見をえた．なお，C_3H/He.Ms. 系マウスの乳癌からえた知見が，腺癌としての一般的特徴によるものかどうかを検討すべく，人体症例についても検索を試みた．

Introduction

It is considered that radiosensitivity is higher in tumor cells adjacent to the blood vessel and lower in those far away from it. In our previous work[18] we investigated solid type Yoshida sarcoma in rats and methylcholanthren-induced sarcoma in mice, and reported that the tumor cells adjacent to the blood vessel or muscle bundle showed higher radiosensitivity as well as vigorous growth, while those away from them were lower in both radiosensitivity and growth rate. These experimental data were confirmed also in human cancers of uncomplicated tissue structure such as carcinoma simplex and fibrosarcoma. In these tumors, therefore, oxygen concentration in tumor tissue and proliferation potency of tumor cells were important factors determining the sensitivity.

We know that in radiation therapy the effect is generally elevated when the tumor tissue is sufficiently supplied with oxygen.[1)2)4)5)6)8)10)11)12)13)20)21)24)25)26)] In some types of tumor, however, especially in

adenocarcinoma, it is said[28] that good effect can not be expected so much by oxygen supply. It has further been pointed out that the so-called "Non-growth fraction", that is, a tumor cell population which has stopped growth, is extensively present in mammary cancer which develops spontaneously in C_3H strain mice.[14)15)] This suggests that in adenocarcinoma the factor modifying the sensitivity may be defferent from that in Yoshida sarcoma or MC-induced sarcoma.

In the present experiment, which aims to elucidate this point, spontaneous mammary cancer in C_3H strain mice was transplanted into the thigh muscle of the same strain mice, and the first generation tumor was examined with respect to relation between histological feature and radiosensitivity. Moreover, autopsied cases of human tumor were also referred to.

The results disclosed that tumor cells which were considered to pertain to "Non-growth fraction" were frequently present in the tumors with strong tendency of differentiation, forming the single-layered glandular lumen, and that they were also resistant to radiation. On the other hand, the part considered as "Growth fraction" was found lacking in normal tissue imitativeness and showing solid proliferation and higher radiosensitivity. It was further known that mammary cancer of mouse which showed regression to a certain extent after several fractionated irradiations, but which thereafter remained in a dormant state showing neither regression nor growth, mostly possessed a differentiated glandular structure. In adenocarcinoma, therefore, the sensitivity can not be considered dependent exclusively on the blood vessel, but is assumed to be determined more emphatically by "Differentiation" of the tumor cells. Differentiation generally reduces the sensitivity, but when some alteration is elicited in the environmental condition, differentiated cells are capable of resuming growth, thus becoming the cause of relapse.

Materials and Methods

Animals: C_3H/He.Ms. strain, 6-8 weeks old male mice propagated in our department by mating the litter mates.

Tumor: The first generation tumor obtained by transplantation of mammary cancer, histologically papillary adenocarcinoma, which developed spontaneously in mice during breeding in our department.

Transplantation: Tumor-bearing mice were sacrificed, the tumor tissues were crushed on a double stainless steel net, suspended in Eagle's solution, and the resultant tumor liquid was transplanted into the thigh muscle of normal mice. Each suspension contained 10^7 cells.

Irradiation: Tumor-bearing mice were anesthetized with thiopental sodium, each placed in a lead box, and the tumortransplanted right hind limb alone was made to put out of a hole to be exposed to irradiation. Specification of radiation; 180 kv, 25 mA, 0.5 Cu + 0.5 Al, 20 cm, 10 × 5 cm^2, 1 mm Cu, 319 R/m.

Histologic section: The irradiated tumor-bearing animals were sacrificed at adequate times, and the tumor tissue after fixing in a 10% buffered formalin or Carnoy solution, and embedding in paraffine, was cut into thin sections, which were stained by H.E., PAS, Mallory, Van Gieson, PTAH staining and PAP impregnation for microscopical observation.

Microautoradiography: The tumor bearing mice intraperitoneally injected with 1μCi/g of ^3H-thymidine, and 45 minutes later sacrificed to take out the tumor. After formalin fixing and paraffine embedding, it was processed by the dipping method using Sakura NR-M_2 emulsion, and poststained with methyl-green pyronin.

Results

1. Histological picture of the transplanted tumor

Mammary cancers, spontaneously developing in C_3H/He.Ms. strain mice, can all be classified under the category of adenocarcinoma. Detailed examination of each individual case of them, however, revealed variation in their growth rates and histological pictures. The tumors used in the present experiments appeared to form a carcinoma simplex-like solid cell population with sporadic formation of cysts and glandular lumina and had a weak tendency of differentiation.

Fig. 1. Growth curve of mammary cancer transplanted into the thigh muscle in C_3H strain mice

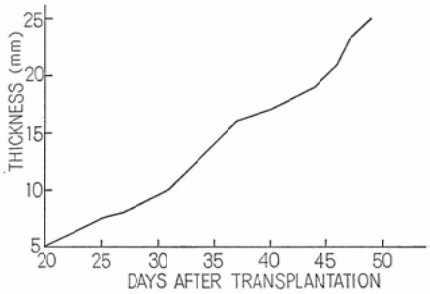

Fig. 2. Regression and regrowth curve of the tumor irradiated with 1000 R

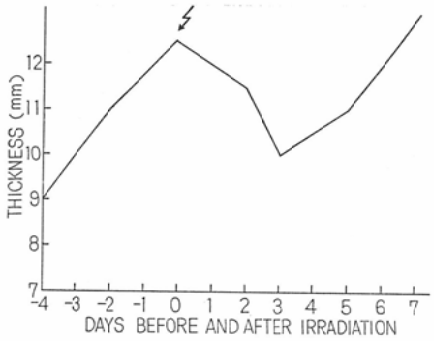

About 20 days after transplantation into the thigh muscle, the tumor became palpable, and then became swollen as shown in Fig. 1 until at last its diameter attained 25 mm. The histological picture was similar to that of the primary cancer, being divided into two portions—one exibiting carcinoma simplex-like solid growth, and lacking normal tissue imitativeness, and the other having marked formation of glandular lumen, and being regarded as differentiation-type adenocarcinoma. There were however, transitional picture between them, and the difference seemed not essential. In the portion of the carcinoma simplex like structure, mitosis was remarkable, giving mitotic index of about 2%; also uptake of ^{3}H-TDR was observed in over 30% of the total tumor cells. In contrast with this, the portion with grandular structure gave lower mitotic index and this value varied in different parts. Especially, mitotic index and ^{3}H-TDR uptake were lower in the tumor cell population showing gland epithelium-like disposition, being below 10% of those in the population of the simplex cancer-like structure. Growth picture of capsular epithelial cells, tumor cells, of the cysts, containing colloidal protein fluid, was scarcely visible. (Photo 1).

Relation between the blood vessel within the tumor tissue and proliferation potency of the tumor cells was not so clear in this tumor as in the solid-type Yoshida sarcoma or in MC-induced sarcoma, since the whole of the tumor was richly vascularized.

As for the relation between the size and histological picture of the tumor, no evident change was visible in the latter while it grew from the palpable state to the size with thickness of 16 mm. When the thickness was over 16 mm, secondary changes such as hemorrhage and infection were added, and the picture was considerably variable from tumor to tumor. Therefore, in the present experiments, irradiation was commenced as a rule when the thickness of the tumor was 12 mm $\pm$ 1 mm.

Table 1. Time necessary for showing minimum diameter of tumor after irradiation with 1000 R

	Days 1	2	3	4	Total	Mean
No. of Tumor	6	2	3	4	15	2.3 ± 1.3 days

Table 2. Time necessary for returning to the initial size after irradiation with 1000 R

	Days 4	5	6	7	8	9	10	Total	Mean
No. of Tumor	1	1	2	5	3	1	2	15	7.3 ± 1.6 days

2. Temporal change in histological picture after single exposure with 1000R.

When 1000 R irradiation was applied to the tumor, the majority showed regression and regrowth curve as shown in Fig. 2, though time necessary for regression and regrowth were varying in different individual tumors (Tables 1,2). Examination of this curve with reference to the histological picture revealed that at 3 hours after irradiation only inhibition of mitosis but not destruction of the cells took place, and that at 6–12 hours, degeneration and destruction were under way. This was especially prominent in the portion of the carcinoma simplex-like structure exhibiting vigorous growth. But at these time, shrinkage of the swelling was not yet visible. After 24 hours, however, the swelling began to be shrunken, and in the histological picture, resorption of destroyed cells and consequent formation of intercellular space became visible. But no remarkable change was observed in the tumor cell group of glandular structure. After 48 hours the tumor had shrunken to the minimum size in many cases, and in the histological picture, the destroyed cells had already been absorbed, and the typical adenocarcinoma with marked glandular structure was demonstrated. At 3–5 days after the irradiation, mitotic figure began to appear in the tumor cells of glandular disposition, and the tumoragain started to grow. When the swelling returned to the initial size, that is, the size at the time of irradiation, the tumor cell population of the carcinoma simplex-like structure with vigorous growth reappeared, and the histological picture returned to the preirradiation one. (Photos. 2, 3, 4).

Differentiated tumor cells which were mingled in the tumor tissue showed decrease both in growth rate and the sensitivity. They were, however, assumed to have potency to start vigorous growth again when the environmentturns favorable for them.

3. Histological picture of tumor assumedly in "dormant state"

When the tumor transplanted into the thigh muscle attained 12 mm ± 1 mm in thickness, 2500

Fig. 3. Regression and regrowth curve of the tumor irradiated

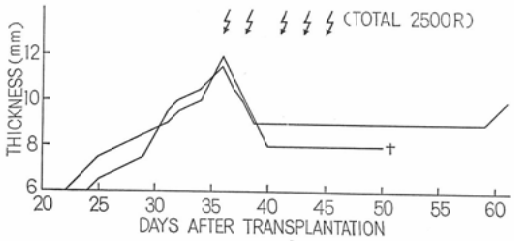

R/10 days irradiation was administered in combination with intra-tumor injection of Ametohepazon[17)27)], which has sensitivity-increasing effect. And the tumor was brought to a state, though during a short period, in which neither growth nor regression occurred, as shown in Fig. 3. This can be considered as a dormant state. Autopsy during this time (Fig. 3 +) disclosed the tumor with rough surface owing to the presence of vesicles. Histologically, tumor cells exhibited conspicuous differentiation with proliferation of fibrous connective tissue and formation of glandular lumen, but the growth picture of the tumor was not seen at all. And the portion of the carcinoma simplex-like structure had almost disappeared. (Photos. 5, 6).

Discussion

Radiosensitivity of tumor was reported in our previous paper[18)] to be dependent on special relation with the blood vessel, and in the present paper, on the grade of its differentiation. And in both cases, sensitivity was higher in the portion of vigorous growth, and lower in the portion of suppressed growth. In the mammary cancer of C_3H strain mice, the sensitivity was lower in differentiated tumor cellseven if they were found adjacent to the blood vessel, indicating that oxygen effect might not be significant in this case. Therefore the important problem in the radiotherapy of tumor containing differentiated cells is not how to elevate oxygen concentration in the tumor tissue but to find out the factor which controls cell differentiation and to apply it to the therapy. According to Bullogh *et al*[3)]., it is a substance called Chalone which controls differentiation and mitosis of the cell. They explain that when the concentration of Chalone is higher, progenitor cells turns mature cells, and that when the concentration lowers, mature cells returns to progenitor cells. We did not attempt in the present experiment to demonstrate the presence of Chalone, but the finding we obtained was phenomenally in conformity with their suggestion. Namely we found that the tumor cells remaining after the irradiation had strong tendency of differentiation and low growth potency, but that in the stage of relapse, the differentiated cells were on the way of transformation into undifferentiated cells with marked tendency of proliferation. We considered that this fact could be applied to therapy in the form of fractionated irradiation. We practically attempted it and found it evidently significant[19)].

Using ^{3}H-thymidine Mendelsohn[14)15)] autoradiographically examined spontaneous mammary cancer in C_3H mice, and pointed out that among the living tumor cells were found about 70% cells which had stopped growth. In our experiments, in which pulse labeling was made, ^{3}H-thymidine uptake was not ampule in differentiated tumor cells, and there were only small number of labeled cells. Probably these differentiated cells may play the principal role in the Mendelsohn's non-growth fraction.

Now we want to consider about dormant cell[7)9)]. There are cases of human cancer, which relapse several years after treatment. This is difficult to explain without assuming that they have a period during which the growth is stopped, or they need a long time in passing to the next generation, that is, they have a dormant state. In our present experiment we succeeded to produce a tumor which exhibited neither growth nor regression during a period though it lasted only about 20 days. It consisted of perfectly differentiated cells. The notion of dormant cell is not yet definitely established, and we can not hastily regard it as differentiated cell. It is, however, possible that a differentiated cell as a kind of dormant cell may become a cause of the future relapse of the tumor.

It is said that the characteristic of the primary tumor is gradually lost as it is transplanted through

successive generations[16)23)]. Since we used the tumor transplanted into the thigh muscle we may naturally suspect that it can not represent the genuine nature of the tumor. It is, however, accepted that the characteric of the primary tumor is retained relatively well as long as 3 generations. We examined the tumors of the first generation after transplantation, and histologically they were not different from the primary tumor. Consequently there seems to be no question as to the alteration resulting from the transplantation. It is, however, questionable whether the data obtained from the mammary cancer of the C_3H mice can be considered as inherent to the adenocarcinoma in general inclusive of human cancer. So we are now carrying out investigation on this point with human cancer. Up to date, the autopsy findings in our department supported our results from experimental animals. Below are given 2 case reports.

Case 1. A 53 years old female. Pulmonary cancer originated in the right main bronchus. The hilar portion including the primary focus was irradiated with 4200 R/61 days of ^{60}Co. Ten days after the termination of the irradiation she died owing to metastasis to the whole body. It was found at autopsy that the pulmonary metastatic tumor in the non-irradiated area showed solid growth of near circular or elliptic shaped cells with rich chromatin, only partially manifesting glandular structure, whereas in the irradiated tumor tissue, fibrous connective tissue was markedly proliferated, and in it was seen remnant of the tumor tissue with conspicuous glandular structure. This seems to indicate that the tumor cells which were differentiated to form glandular structure were resistant to irradiation. (Photos. 7, 8).

Case 2. A male aged 56, with stomach cancer complicated with peritonitis carcinomatosa. Irradiation with 2400 R/17 days of ^{60}Co failed to bring about either regression of the tumor or decrease in ascitic fluid. On the 3rd days after the final irradiation, he died owing to general asthenia. Autopsy disclosed that the tumor was typical signet-ring-cell mucoid carcinoma consisting mostly of PAS-positive signet-ring cells, and that metastatic foci were extensively formed in the pancreas, liver and lymph nodes. The findings indicative of the effect of irradiation could not be found in the PAS-positive cells, but PAS-negative cells observed in some parts of the liver and pancreas exhibited a picture of severe degeneration including pyknosis and destruction. The lower sensitivity of the PAS-positive cells may be attributed to their mucous degeneration or to their being highly differentiated to produce mucous. We are inclined to the latter view because we observed the mitotic figure in the PAS-positive signet-ring cells, and because culture of ascitic tumors inclusive of the above mentioned case which was performed by Satoh *et al*[22)]., of our department showed mitoses and proliferation of PAS-positive cells. (Photos. 9, 10, 11, 12).

Summary

Histological investigation was performed on the relation between tissue structure and radiosensitivity of tumor. The materials are tumors of the first generation after transplantation of the spontaneous mammary cancer of C_3H/He.Ms. into the thigh muscle of mice of the same strain.

Histologically, the used tumors were adenocarcinoma of relatively lower differentiation, consisting mainly of solid proliferation of cubic or cylindric cells with near circular nuclei, and partly forming glandular lumen. In a group of the tumor cells, exhibiting carcinoma simplex-like solid proliferation, the growth was vigorous and the radiosensitivity was higher, while in the other cell group, exhibiting glandular structure and tendency of differentiation, the growth potency as well as the sensitivity was lower. In the previous experiments[18)] with Yoshida sarcoma and methylcholanthren-induced sarcoma we observed that there was correlation between growth potency and radiosensitivity of tumor and that this was depen-

Mammary cancer in C-H/He. Ms. strain mice

Photo. 1. Non-irradiation. Carcinoma simplex-like structure at the left and glandular structure at the right are seen.

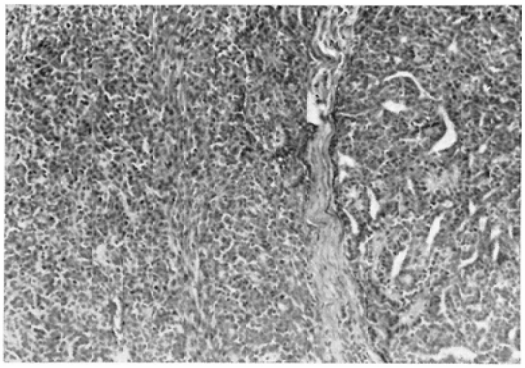

Photo. 2. At 18 hours after irradiation with 1000 R, typical glandular structure are seen remarkably.

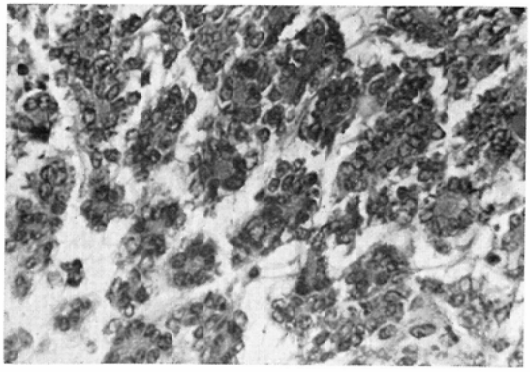

Photo. 3. At 3 days after irradiation with 1000 R, carcinoma simplex like structure with vigorous grow th reappear.

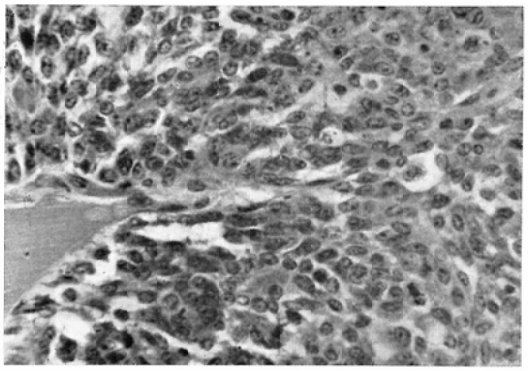

Photo. 4. The same section as the left. Mitotic figures appear in the cells of glandular structure.

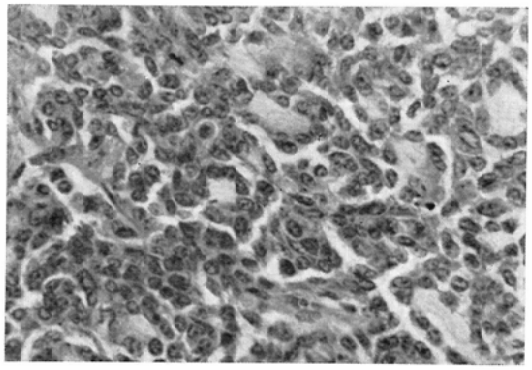

Photo. 5. The tumor which is considered as a dormant state shows conspicuous proliferation of fibrous connective tissue and formation of glandular lumen.

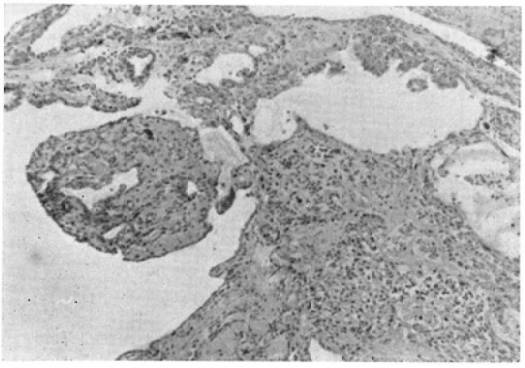

Photo. 6. Detail of the same as the left.

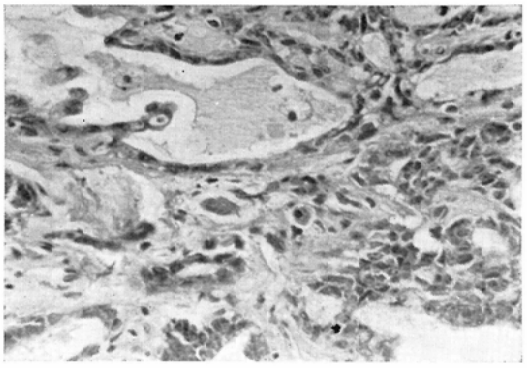

Case 1 Lung cancer

Photo. 7. Non-irradiated part.

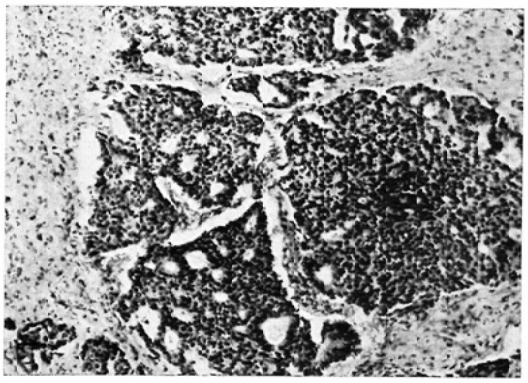

Photo. 8. Irradiated part with 4200 R.

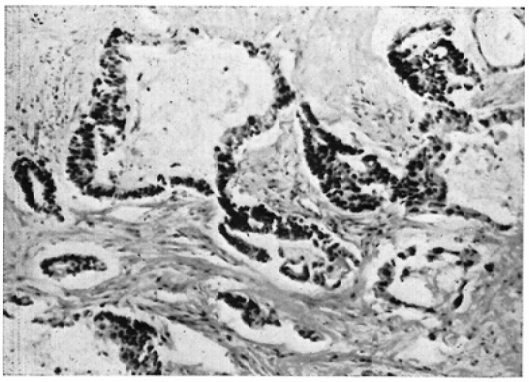

Case 2. Stomach cancer

Photo. 9. Non-irradiated PAS-positive tumor cells.

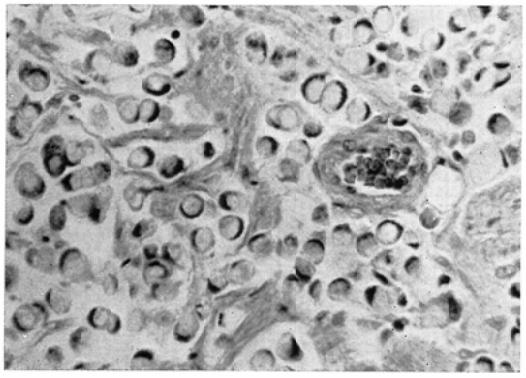

Photo. 10. Irradiated PAS-positive tumor cells show no change histologically.

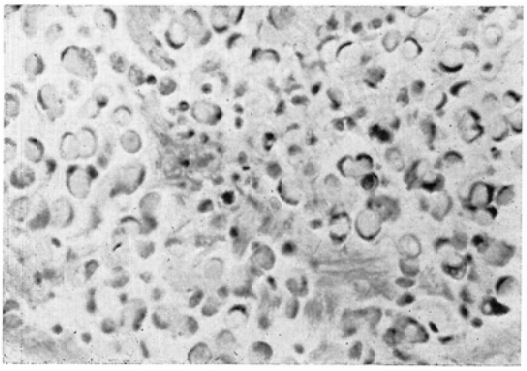

Photo. 11. Non-irradiated PAS-negative tumor cells.

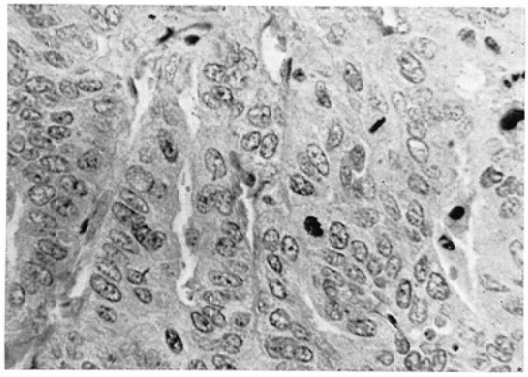

Photo. 12. Irradiated PAS-negative tumor cells exhibit a picture of severe degeneration.

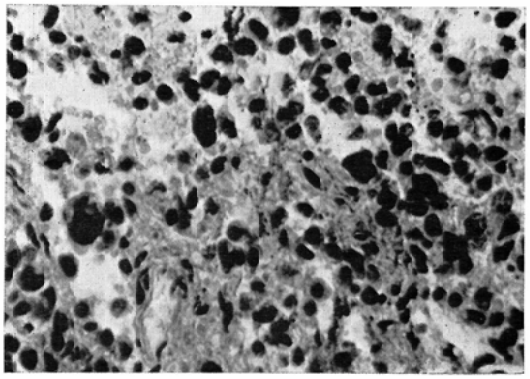

dent on the distance between tumor cells and the blood vessel. In the mammary cancer of C_3H/He.Ms. mice, however, the sensitivity was not always determined by the distance from the blood vessel, but the findings indicated that it was rather the differentiation of the tumor which played a more important role in determing the growth potency as well as the sensitivity of tumor. Now we are continuing investigation on human cases in order to know whether the findings obtained from the mammary cancer of C_3H/He. Ms. strain mice are inherent to adenocarcinoma in general.

Acknowledgement

Grateful acknowledgement is made to Dr. Takashi Okonogi for his encouragement throughout this investigation and Mr. Takashi Katsuyama for technical assistance.

References

1) Belli, J.A., et al.: Nature, 211, 662, 1966.
2) Belli, J.A., et al.: J. Natl. Cancer Inst., 38, 673, 1967.
3) Bullogh, W.S.: Cancer Res., 25, 1683, 1965.
4) Churchill-Davidson, I., et al.: Brit. J. Radiol., 30, 406, 1957.
5) Churchill-Davidson, I., et al.: Brit. J. Radiol., 39, 321, 1966.
6) Clifton, K.H., et al.: J. Natl. Cancer Inst., 36, 965, 1966.
7) Fisher, B., Fisher, E.R.: Science, 130, 918, 1959.
8) Fowler, J.F., et al.: Brit. J. Radiol., 36, 77, 1963.
9) Hadfield, G.: Brit. Med. J. 2, 607, 1954.
10) Gray, L.H., et al.: Brit. J. Radiol., 26, 638, 1953.
11) Gray, L.H.: Brit. J. Radiol., 403, 1957.
12) Gray, L.H.: Am. J. Roentgenol., 85, 803, 1961.
13) Hewitt, H.B., Wilson, C.W.: Brit. J. Cancer, 13, 69, 1959.
14) Mendelsohn, M.L.: J. Natl. Cancer Inst., 28, 1015, 1962.
15) Mendelsohn, M.L.: Cellular Radiation Biology, 498–513, The Williams and Wilkins Company, Baltimore, 1965.
16) Niibe, H.: Kitakanto, 14, 486, 1964. (Japanese)
17) Niibe, H., et al.: Nipp. Act. Radiol., 27, 995, 1967.
18) Niibe, H., et al.: Nipp. Act. Radiol., 28,1256,1968.
19) Niibe, H.: to be published.
20) Powers, W.E., Talmach, L.J.: Nature, 197, 710, 1963.
21) Powers, W.E., Talmach, L.J.: Radiology, 83, 328, 1964.
22) Satoh, I.: Personal communication.
23) Satoh, K.: Kitakanto, 13, 297, 1963. (Japanese)
24) Suit, H., Maeda, M.: Am. J. Roentgenol. Radium Therapy, Nucl. Med., 96, 177, 1966.
25) Thomlinson, R.H.: Brit. J. Radiol., 36, 89, 1963.
26) Thomlinson, R.H.: Radiotherapy 1, 52-72, Butterworths, London, 1967.
27) Tobe, T., Niibe, H., Koike, N., Yonome, I.: Nipp. Act. Radiol. 27, 987, 1967.
28) Wildermuth, O.: Am. J. Roentgenol., 96, 171, 1966.