The University of Osaka
Institutional Knowledge Archive

Title	A Study of Patients with Bronchiolitis Who Show almost Normalcy in Chest X-ray Films-From the Viewpoint of Radiodiagnostics-
Author(s)	田中, 満; 佐藤, 勝; 小林, 弘祐 他
Citation	日本医学放射線学会雑誌. 1985, 45(6), p. 821-827
Version Type	VoR
URL	https://hdl.handle.net/11094/17662
rights	
Note	

The University of Osaka Institutional Knowledge Archive : OUKA

https://ir.library.osaka-u.ac.jp/

The University of Osaka

日本医放会誌：45（6），821—827，1985（昭60）

A Study of Patients with Bronchiolitis Who Show almost Normalcy in Chest X-ray Films
—From the Viewpoint of Radiodiagnostics—

Mitsuru Tanaka
Department of Diagnostic Radiology, School of Medicine, Keio University
Masaru Satoh, Hirosuke Kobayashi and Fumihiro Yamasawa
Department of Internal Medicine, School of Medicine, Keio University

Research Code No. : 506

Key Words : Bronchiolitis, Selective alveolar bronchography, Small airway disease

胸部X線写真上，ほとんど異常を認められない細気管支炎例の検討
—X線診断学的立場から—

慶応義塾大学医学部放射線診断部
田　中　　満
慶応義塾大学医学部内科
佐藤　勝　小林　弘祐　山沢　文裕

（昭和59年10月18日受付）
（昭和60年1月9日最終原稿受付）

胸部X線写真上，ほとんど異常を認められない細気管支炎を検討して，細気管支炎の臨床的診断基準の確立および病態生理の解明の足がかりを得ることを目的とした．

臨床所見，呼吸生理学的検査，X線検査，肺生検などから臨床的に細気管支炎と診断した44例の中から胸部X線写真上，そとんど異常を認められない9例を対象として検討した．次のような結果をえた．

（1）呼気の胸部X線写真は，細気管支炎を診断する上に必要である．

（2）選択的肺胞気管支造影で，呼吸細気管支から終末細気管支にかけて，狭小，分岐，欠如，肺胞像出現不均等の所見が多くみられ，特に狭小が顕著な所見である．

（3）スパイトメトリーでも全く異常がない症例では，中枢気道に病変がおよんでなく，また気道感染を起こしていない細気管支炎である場合が多い．

（4）細気管支炎を診断する上で，胸部X線写真，選択的肺胞気管支造影は必要な検査である．

Recently, the pathogenesis, clinical course, and pathology of bronchiolitis have aroused considerable concern. Accordingly, pulmonary function test and morphological diagnostic methods have improved, and diseases characterized by lesions in the peripheral airways have been confirmed. In spite of this progress, it is well known that there are still many lesions that cannot be identified. Thus, elucidation of pathophysiology of bronchiolitis, in which the main lesion is present in the bronchioles, is one of the most important subjects in

the field of respiratory disease.

At present, there are various concepts and diagnostic standards applied to bronchiolitis, but, in spite of various proposals, there is still little unification or uniformity. Up to now, we have carried out clinical studies of patients with bronchiolitis by respiratory physiological and morphological methods, using general clinical findings previously obtained as an aid.

In this report, in order to study bronchiolitis radiodiagnostically, we chose patients who had been diagnosed as having bronchiolitis by various tests and who showed almost normalcy in chest x-ray films during inspiration. These patients were studied for the purpose of establishing clinical diagnosis for bronchiolitis.

Subjects and methods

Of 44 patients who visited our hospital during the period from July, 1978 to December, 1982 and who were clinically diagnosed as having bronchiolitis on the basis of clinical findings and the results of pulmonary function test, x-ray examinations and transbronchial lung biopsy (TBLB), nine (six men and three women) who had almost normal x-ray findings during inspiration were selceted as subjects. They ranged in age from 27 years to 65 years, with an average age of 44.6 years. With regard to past histories, paranasal sinusitis and pneumonia had been observed in one and two patients, respectively. Also, one patient had a past history of inhalation of ammonium gas. The remaining five patients had no remarkable past histories (Table 1).

The subjects included four smokers and five nonsmokers. Clinically, cough was present in eight patients, sputum in six, and dyspnea in seven. In six patients, vesicular sounds and crepitation were heard (Table 2).

The following procedures were performed on the selected patients: Pulmonary function tests plain chest x-ray examination during expiration and inspiration, magnification radiography, selective alveolar bronchography (SAB), with the use of three to four times magnification, endoscopic examinations of peripheral airways, TBLB, spirometry and alveolar-alterial O_2 tension difference ($AaDo_2$).

SAB was performed according to the method previously reported in which about 2 ml of aqueous dionosil was infused through a prewedged 6.6 F KIFA RED catheter.

Table 1 Clinical features I

1. Number of patient 9
2. Sex Male 6 Female 3
3. Age (average) 44.6
4. Past history Nasal emphyema 1
   Pneumonie 2 Toxic gas 1
   No particular 5
5. History of smoking
   Smoker 4
   No smoker 5

Table 2 Clinical features II

	Patient								
	1	2	3	4	5	6	7	8	9
Age, yr.	47	43	56	27	46	65	36	37	44
Sex	F	F	M	M	M	M	F	M	M
Cough	+	−	+	+	+	+	+	+	+
Sputum	−	−	+	−	+	+	+	+	+
Dyspnea	+	+	+	+	+	−	+	−	+
Respiratory failure	−	+	−	−	−	−	−	−	−
Cor pulmonale	−	−	−	−	−	−	−	−	−
Polycythemia	−	−	+	−	−	−	−	−	−
Clubbing	−	−	−	−	−	−	−	−	−
Inspiratory rales	−	+	−	−	−	+	+	+	+
Stridor	−	+	−	−	−	−	−	+	+
Chest pain	−	−	−	+	−	−	−	−	−

Results

Chest x-ray findings

In chest x-ray films (Fig. 1) taken during inspiration, almost abnormal findings were observed in any subjects, whereas in the films during expiration, diffuse miliary nodular shadows were enhanced in 55.6% of the subjects. In magnification radiographic findings simultaneously performed, abnormal findings were observed in 28.6% of the subjects.

SAB findings and morphological classification

SAB findings in the peripheral airway included narrowing, dilatation, obstruction, poor branching, tortuosity, alveolar ductectasis, alveolar abnormal figure and alveolar uneven filling. Narrowing and dilatation in SAB findings were evaluated by actual measurement with a tube in contrast with KIEF RED catheter of 2.0 mm in outer diameter used in SAB. The normal range from the respiratory bronchioles to the terminal bronchioles of 0.5 to 0.6 mm was obtained from Weible's calculation, the measurement value from molder samples by Pump, and the actual measurementof Horsfield et al. As a result (Table 3), narrowing, poor branching, and alveolar uneven filling were found to be frequent SAB findings among the patietns in this study.

Our morphological classification (Table 4) has already been reported as follows: the group with narrowed terminal bronchioles (Type I); the group with dilated terminal bronchioles (Type II); the group with alveolar ductectasis (Type III); and the group with alveolar abnormal figures (Type IV). Futhermore, according to the degree of abnormality, those with dilatation of the terminal bronchioles (Type II) are divided into high

Fig. 1 The left is the chest film in inspiration, and the right is that in expiration.

Table 3 Selective alveolobronchographic findings

n=9

SAB findings	Patient 1	2	3	4	5	6	7	8	9
Obstruction	−	−	−	−	−	−	−	+	−
Dilatation	−	−	−	−	++	−	−	−	−
Narrowing	++	++	−	+	−	+	−	+	−
Poor branching	−	−	+	−	++	+	−	+	−
Tortuosity	−	−	−	−	++	−	−	−	−
Alveolar ductectasis	−	−	−	−	++	−	−	−	−
Alveolar uneven filling	−	−	+	−	++	+	−	+	−
Alveolar abnormal figure	−	−	−	−	++	−	−	−	−

Table 4 Classification of the patterns of selective alveolobronchography

I	II a	II b	III	IV a	IV b	normal	N
5	0	1	0	0	0	2	9

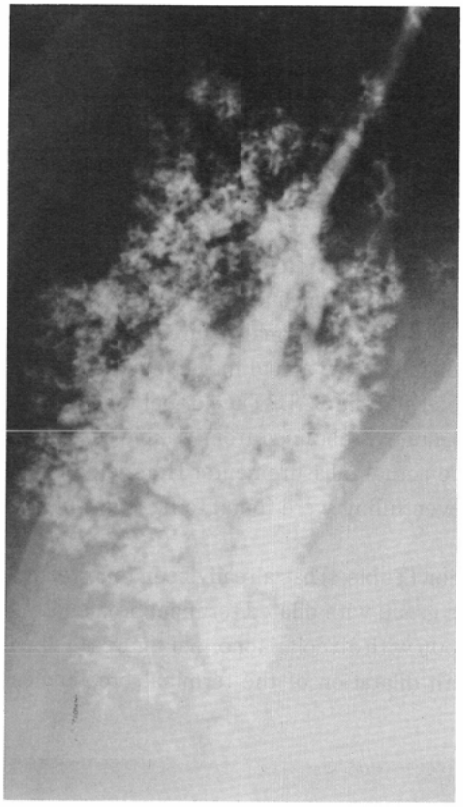

Fig. 2 This is the group with narrowed terminal bronchioles (Type I).

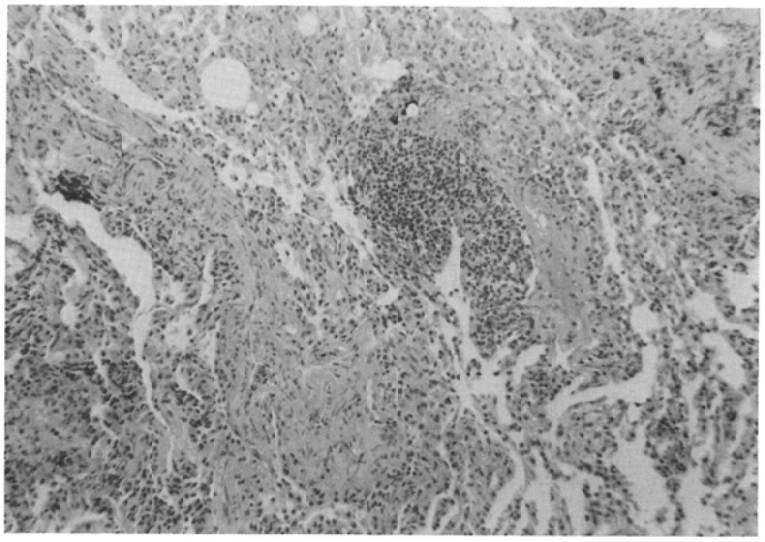

Fig. 3 A connective tissue around bronchiole is edematous and fibrotic hypertrophy. There are an accumulation of mononuclear infiltration and of polymorphonuclear leukocytes.

Table 5 Scores of selective alveolobronchographic findings

n=9

SAB findings	Grade 0	I	II	III	Score
Obstruction	0	1	0	0	1
Dilatation	0	0	2	0	2
Narrowing	0	3	4	0	7
Poor branching	0	3	2	0	5
Tortuosity	0	0	2	0	2
Alveolar ductectasis	0	0	2	0	2
Alveolar uneven filling	0	3	2	0	5
Alveolar abnormal figure	0	0	2	0	2

Table 6 Pulmonary function data

n=9

% VC		$FEV_{1.0}$ %	
Normal	Abnormal	Normal	Abnormal
8	1	6	3

$\dot{V}_{25}$		$\dot{V}_{50}$	
Normal	Abnormal	Normal	Abnormal
4	5	5	4

$AaDo_2$		
~25	26~35	36~
6	2	1

dilatation (Type IIa) and slight to moderate dilatation (Type IIb); and those with alveolar abnormal figures (Type IV) are divided into highly abnormal (Type IVa) and slightly to moderately abnormal (Type IVb).

Five subjects in this study were classified as Type I, (Fig. 2, 3) one as Type II and three as others. As for three with other finidings, no clear figure was observed in two, and only poor branching and alveolar uneven filling were observed in one. Abnormality was observed in all chest x-ray films taken during expiration of three patients who showed no clear findings or only poor branching and alveolar uneven filling.

SAB score (Table 5)

In order to totally evaluate morphological changes found by SAB, we classified the SAB findings by scoring them as 0 (no clear findings), 1 (slightly abnromal), 2 (moderately abnormal) and 3 (highly abnormal) using parameters. The total score was found to be high in findings of narrowing, poor branching, and alveolar uneven filling; it was the highest among the subjects who showed narrowing.

Pulmonary function (Table 6)

In respect to ventilatory function of subjects, no abnormal findings were present for %VC, $FEV_{1.0}$% and $\dot{V}_{50}$ in eight, six and five of the nine subjects, respectively.

On the other hand, abnormal $\dot{V}_{25}$ findings were observed in five of the nine subjects, the highest among the abnormal findings. $AaDo_2$ was found to be increased in all subjects. Also, there were many subjects in whom PaO_2 (partial pressure of arterial O_2), a base of $AaDo_2$, was decreased. Partial pressure of arterial CO_2 and arterial pH both remained within the normal range in many subjects.

Discussion

A clinical pathological concept of bronchiolitis has been proposed by Lange based on an earlier report of Reynand. Recently, the importance of bronchiolitis in chronic bronchitis has been reported, attracting attention because of new ideas and viewpoints regarding this disease. However, theories and clinical diagnostic standards have not yet been unified.

Therefore, it is necessary to establish a clinical diagnostic standard for bronchiolitis, and we studied subjects in order to attempt this.

Chest x-ray findings of bronchiolitis are variable and contain diffuse miliary nodular shadows, linear shadows, reticular shadows and hyperinflation. In recent chest x-ray findings of diffuse panbronchiolitis, diffusely disseminated fine nodular shadows and hyperinflation have been reported. It has been especially noted that hyperinflation is found at the early stage of the lesion.

In our subjects, abnormal findings were scarcely observed in chest x-ray films taken during inspiration, whereas abnormality was present in x-ray films taken during expiration in 55.6% of subjects and in

magnification findings in 22.6%.

Abnormal shadows are formed relative to the spread of the lesion to the pulmonary parenchyma, the degree of infection and retention of secretions in the bronchioles, and the severity of alveolar hyperinflation due to air trapping. If acute inflammation disappears as a result of treatment for bronchiolitis, then miliary nodular shadows become difficult to detect. In our subjects, it is considered that shadow are difficult to detect in the early stage of the lesion because of alveolar hyperinflation attributable to air trapping, but diffuse miliary nodular shadows are enhanced during expiration appearing on the chest x-ray films. Thus, the reason that abnormal shadows are seen during expiration is unknown. Abnormal shadows are not formed to blood vessel shadows.

Therefore, if a patient is suspected of having bronchiolitis, chest x-ray examination should be performed simultaneously during both expiration and inspiration to allow lesions to be more easily found.

Patients who conformed to our criteria for this study showed narrowing, poor bronching and alveolar uneven filling as SAB findings. Also, in some patients who did not demonstrate abnormality by spirometry, hypoxemia relative to abnormally high levels of $AaDo_2$ were present. These results are suggestive of an imbalance in the ratio of ventilation to blood flow, which corresponds well to SAB findings. According to SAB classification, it was found that there were many patients who were classified as Type I, characterized mainly by narrowing of the bronchioles ranging from the respiratory bronchioles to the terminal bronchioles, or showing no clear abnormality. On the other hand, chest x-ray examination was found to be indispensable because abnormal findings were observed in the chest x-ray films during expiration even in two subjects who demonstrated no abnormal SAB findings. Additionally, the results of SAB scoring revealed that narrowing gives the highest score and is considered to be one of the characteristics of patients with bronchiolitis who conformed to our criteria for this study.

According to the results of our study, it is thought that infection plays some role in dilatation of the bronchioles because SAB Type II classification is frequent in bronchiolitis with airway infection and Type I is frequent in bronchiolitis without infection. When this concept is applied to peripheral airway lesion, the number of patients who show abnormality by spirometry increases in proportion to progress in SAB findings from narrowing to slight dilatation to high dilatation. Thus, when these findings are totalled and studied, the findings obtained in the patients who meet our definition explain the slightness of the lesions, and we would like to emphasize that chest x-ray examination plays an important role in diagnosing early bronchiolitis.

Conclusion

1) If bronchiolitis is suspected, chest x-ray films both during inspiration and expiration are necessary.

2) If bronchiolitis is clinically suspected but abnormal findings are scarcaly seen in chest x-ray films and by spirometry, bronchiolitis in which the lesion does not reach large airways and in which airway infection is not present is diagnosed on many occasions.

3) In these cases, narrowing, poor branching and alveolar uneven filling are frequent SAB findings. Narrowing given the highest SAB score. Also, SAB Type I classification is frequent.

4) $AaDo_2$ is necessary in the clinical diagnosis of bronchiolitis because it increases in all subjects.

Chest x-ray films and SAB were confirmed to be important examinations in diagnosing bronchiolitis.

References

1) McFadden ER Jr, Linden DA: A reduction in maximum midexpiratory flow rate. A spirographic manifestation of small airway disease. Amer J Med. 52: 725—737, 1972

2) McCarthy DS, Spencer R, Greene R, Milic-Emili J: Measurement of "closing volume" as a simple and sensitive test for early detection of small airway disease. Amer J Med. 52: 747—753, 1972

3) Tanaka M, Satoh M, Yokoyama T: Study of lesions of the peripheral respiratory tract by selective alveolo-

bronchohgrapy. Jpn J Thorac Dis. 20: 878—884, 1982
4) Andersen HA: Transbronchoscopic lung biopsy for diffuse pulmonary diseases. Results in 939 patients. Chest. 73: 734—736, 1978
5) Tanaka M, Satoh M, Kawanami O, Aihara K: A new bronchofiberscope for the study of disease of very peripheral airways. design and applications. Chest. 85: 590—594, 1984
6) Tanaka M, Satoh M: Morphological classification of lesions in the small airways by selective alveolo-bronchography. Jpn J Clin Radiol. 27: 9—15, 1982
7) Tanaka M, Satoh M, Takeguchi K, Kobayashi H: An approach to analysis of the lesions in the peripheral airways by radiological examination. Nippon acta radiologica. 43: 897—904, 1983
8) Weibel, ER: Handbook of physiology, section 3: Respiration vol 1. American physiological society, Washington D.C., 1964, p. 285
9) Pump KK: The morphology of the finer branches of the bronchial tree of the human lung. Dis Chest, 46: 379—398, 1964
10) Horsfield, K, Cumming G: Morphology of the bronchial tree in man. J Appl Physiol. 24: 373—383, 1968
11) Lange W: Über eine eigentümliche erkrankung der kleinen bronchien und bronchiolen, Dtsch Arch Klin Med. 70: 342—362, 1901
12) Homma H, Yamanaka A, Tanimoto S, Tamura M, Chijimatsu Y, Kira S, Izumi T: Diffuse panbronchiolitis, A disease of the transitional zone of the lung. Chest. 83: 63—69, 1983
13) Gosink BB, Friedman PJ, Liebow AA: Bronchiolitis obliterans, roentgenologic-pathologic correlation. AJR. 117: 816—832, 1973
14) Satoh M, Tanaka M, Yokoyama T, Abe T, Yamaguchi K, Ichinose Y, Kobayashi H: Morphological classification of patients with distal lung lesions by means of selective alveolobronchography and the evaluation of their impaired respiratory function. Jpn J Thorac Dis. 21: 622—630, 1983