Osaka University Knowledge Archive

Title	The medical aspects of the hemidiaphragms on abdominal films
Author(s)	平松, 慶博; 玉川, 芳春; 野辺地, 篤郎
Citation	日本医学放射線学会雑誌. 1974, 34(3), p. 135-145
Version Type	VoR
URL	https://hdl.handle.net/11094/17894
rights	
Note	

Osaka University Knowledge Archive : OUKA

https://ir.library.osaka-u.ac.jp/

Osaka University

The Medial Aspect of the Hemidiaphragms on Abdominal Films

Y. Hiramatsu, M.D.[1] Y. Tamakawa, M.D.[2], T. Nobechi, M.D.[3]

1. Department of Radiology, Teikyo University School of Medicine
2. Department of Radiology, Akita University School of Medicine
3. Department of Radiology, St. Luke's International Hospital (Tokyo)

Research Code No.: *500*

Key Words: *Diaphragm paraspinal line*

腹部X線フィルムに見られる横隔膜陰影について

帝京大学医学部放射線科
平松慶博
秋田大学医学部放射線科
玉川芳春
聖路加国際病院放射線科
野辺地篤郎

(昭和48年11月24日受付)
(昭和49年1月9日最終原稿受付)

横隔膜の内側部は，しばしば腹部写真において，脊柱の外側にそつて下行する陰影として認められる．しかし，これについては今迄にあまりはつきりとしたX線解剖学的記載はなく，またその病的状態における意義についても記載されていない．我々は，この正常像における解剖学的分析を行い，さらにカリエスなどの病的状態についても分析した．また剖検例においてその解剖学的位置を確認した．この正常像および異常像をよく認識することによつて，脊柱あるいはそれに近接した臓器の疾患の診断に役立つことがある．

The Medial Aspect of the Hemidiaphragms on Abdominal Films

The medial aspects of both hemidiaphragms are frequently seen on plain films of the abdomen as paraspinal lines. Although several papers have appeared describing celiac artery compression by the median arcuate ligament of the diaphragm[3)4)] no plain film observations have ever been made concerning the medial aspects of the hemidiaphragms on abdominal films except in Schmidt's text book "Roentgentomographisch-anatomischer Atlas"[5)] published in 1970.

We happened to see an abdominal film which showed the medial aspect of the left hemidiaphragm very clearly and abdominal tomograms showed it to even better advantage. Since then, we have purposely looked carefully at this area of abdominal films, and found that the medial aspect of the left hemi-

diaphragm could be identified on the plain films or films with contrast material in nearly half of the cases. Further attempts have been made reviewing the films from pneumoretroperitoneal examinations to obtain better visualization of this structure. Changes of this anatomical structure by pathological conditions have been postulated. Films of patients with tuberculosis of the dorsal spine and tortuous or dilated aortas were reviewed. Macroscopic and radiographic examinations of autopsy material were also made.

Anatomy

The muscular fibers of the diaphragm are grouped into sternal, costal and lumbar portions.[2] The lumbar segments arise from the medial and lateral arcuate ligaments and from the lumbar vertebrae by two crura, sinistrum and dextrum. The medial arcuate ligament is continuous with the lateral tendinous margin of the corresponding crus. The crura are tendinous structures and blend with the anterior longitudinal ligament. The right crus is larger and longer than the left arising from the anterior surfaces of the bodies and intervertebral discs of the first three lumbar vertebrae, while the left crus arises from the first two lumbar vertebrae (Fig. 1). The bilateral medial arcuate ligaments unite and form the median arcuate ligament.[1]

The Medial Aspect of the Hemidiaphragm on Routine Abdominal Films

Macroscopic and radiographic examinations were made in three cases at the time of autopsy.

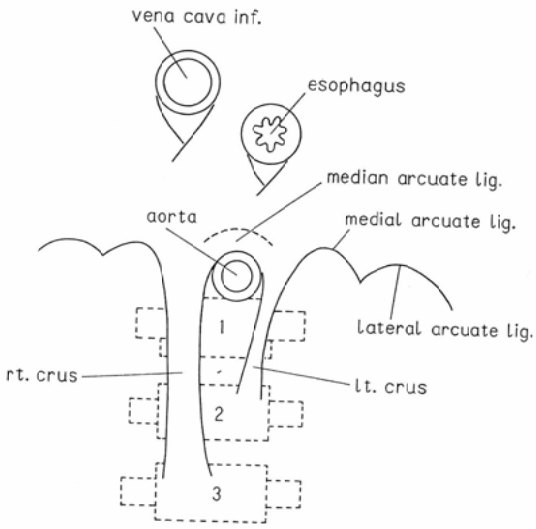

Fig. 1

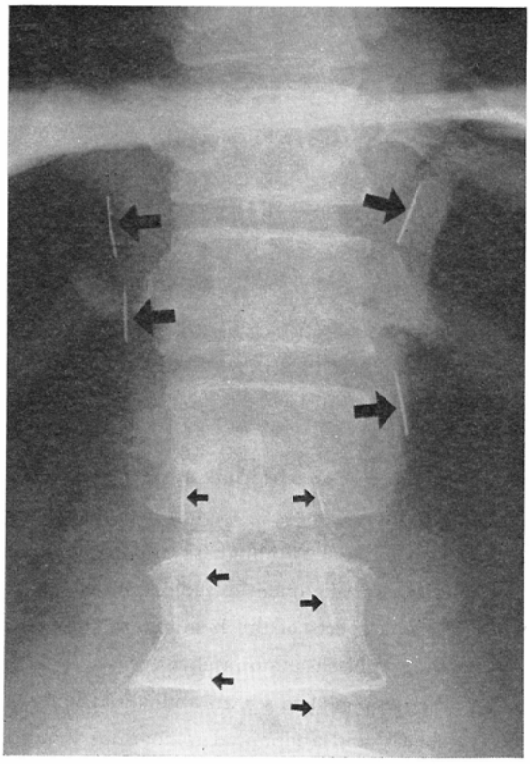

Fig. 2

Films were made with pins in the muscular bundles of the medial aspects of both hemidiaphragms and also in the crura. The crura are superimposed over the spine and could not be seen. The positions of the medial aspects of both hemidiaphragms correspond exactly with those seen in patients (Fig. 2).

The Medial Aspect of the Hemidiaphragm on Routine Abdominal Films

Case 1

A 63 year old hypertensive Japanease female was admitted for evaluation of renal function. A plain film of the abdomen showed a thin opaque line in the left upper quadrant along the spine (Fig. 3A and B). A thinner line is also noted in the right. The lines are well recognized on intravenous urography performed on the following day (Fig. 3C). Tomograms taken during the study demonstrated the linear opacities to be continuous with the hemidiaphragms on each side (Fig. 4). At first, these were thought to be the crura of the diaphragm, but in comparing the anatomy and roentgenograms, it was concluded that the visualized linear opacities are the medial aspect of the hemidiaphragms. The first reason for that conclusion is that the crura are positioned medially and would not be seen on radiographs due to superimposition with the spine, and secondly, the sites of the attachment of the crura are lower than those of the visualized linear opacities.

Case 2

A 40 year old male with a right ureteral stone. A plain film of the abdomen showed the medial aspect of the left hemidiaphragm very clearly, which could be mistaken for gastric folds (Fig. 5).

The Medial Aspect of the Hemidiaphragm on Films for Upper Gastrointestinal Series

The medial aspect of the hemidiaphragm were most frequently seen on the films for gastrointestinal series. Examination of the upper gastrointestinal tract is one of the commonest examinations in Japan and multiple films are taken in various projections and techniques. These are probably the reasons for frequent visualization of this structure on this type of examination.

Case 3

A 58 year old male with gastritis had an examination of the upper gastrointestinal tract. A film made in a slight oblique position showed the medial aspect of the left hemidiaphragm clearly, which could not be seen on the straight PA film (Fig. 6A and B). This fact can be easily explained from their anatomical relationship to the spine.

Demonstration of the Medial Aspect of the Hemidiaphragm on Pneumoretroperitoneum

It was assumed that the medial arcuate ligament might be more clearly demonstrated on the films taken during pneumoretroperitoneal study. From 1967 to 1970, thirteen pneumoretroperitoneal studies were performed. Three cases were unsuccessful in demonstrating the medial aspect of the hemidiaphragm because of either technical failure or presence of tumor in the retroperitoneal space. In all successful cases, the medial aspect of the hemidiaphragms were identified to some extent, but the demonstration was limited to the superior portions. The inferior portions which are attached to the spine were not well demonstrated (separation of the soft tissues of the retroperitoneum by air might not have extended into these deep structures).

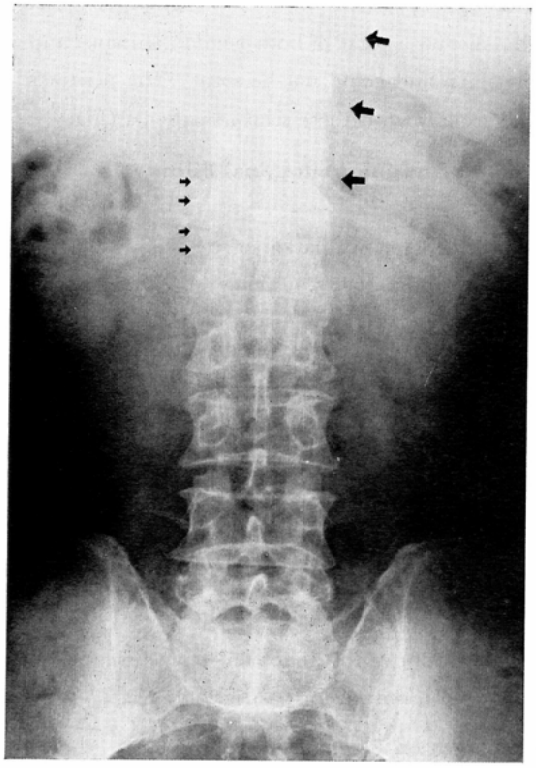

Fig. 3A

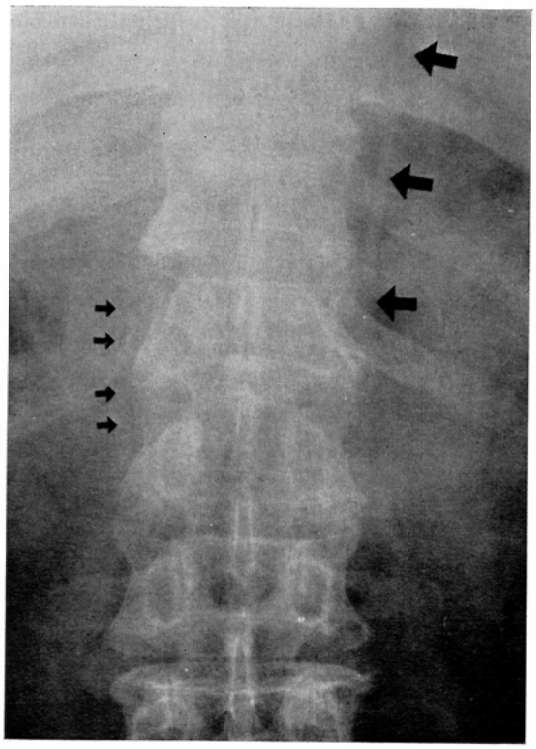

Fig. 3B

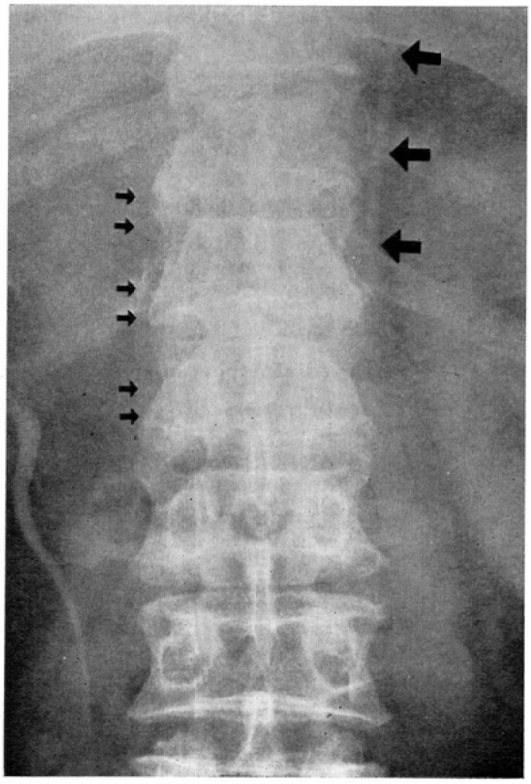

Fig. 3C

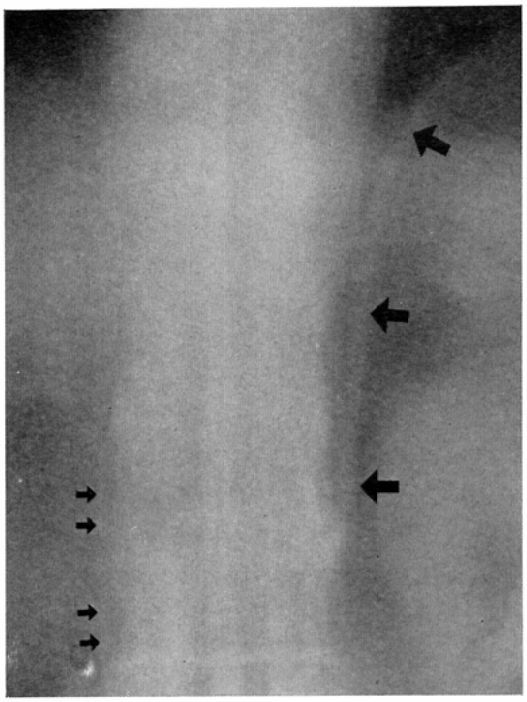

Fig. 4

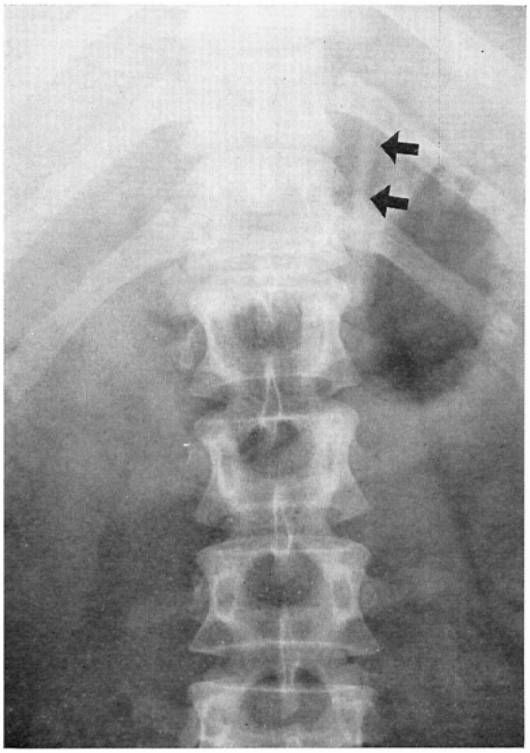

Fig. 5

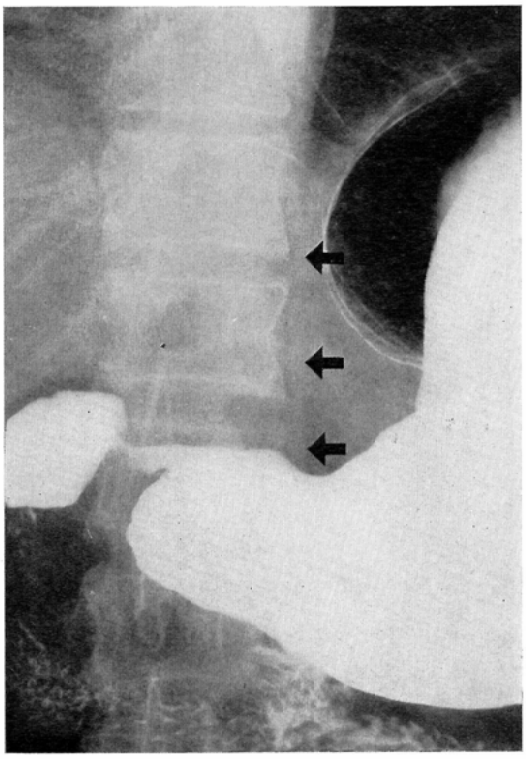

Fig. 6A

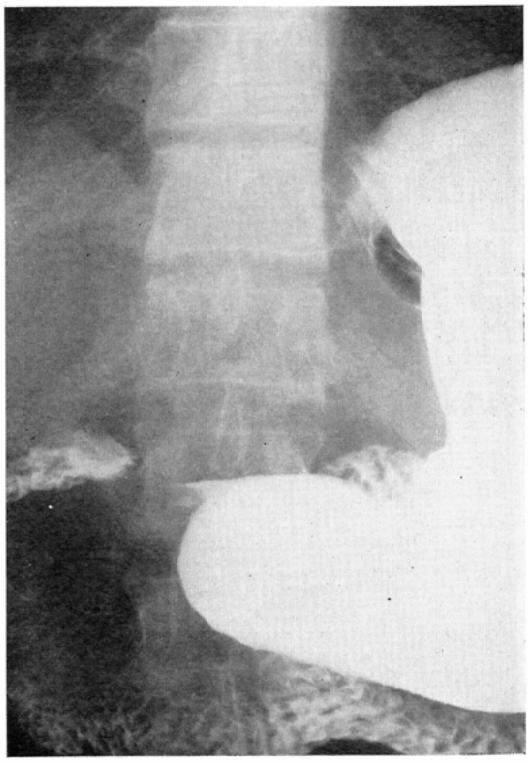

Fig. 6B

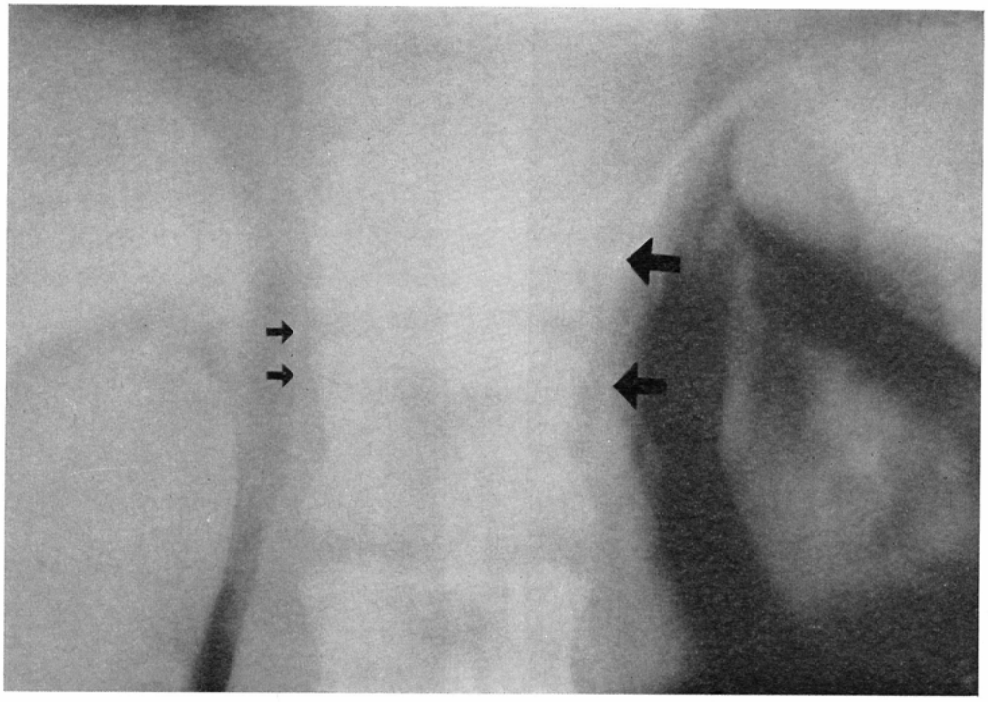

Fig. 7

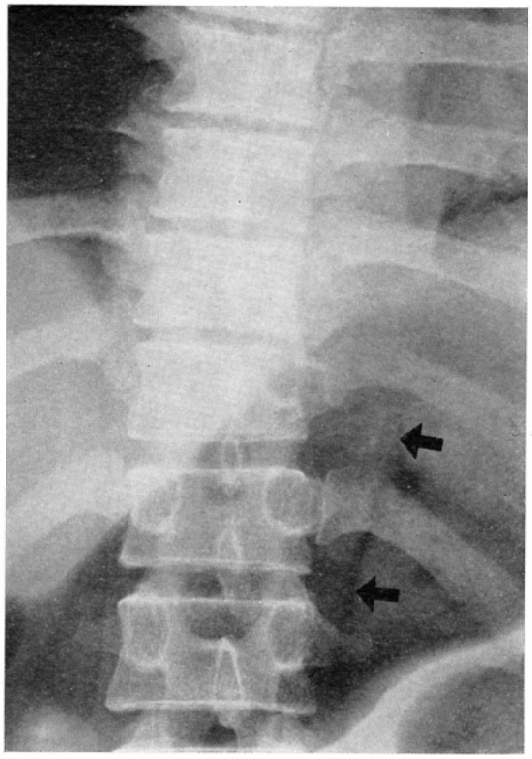

Fig. 8A

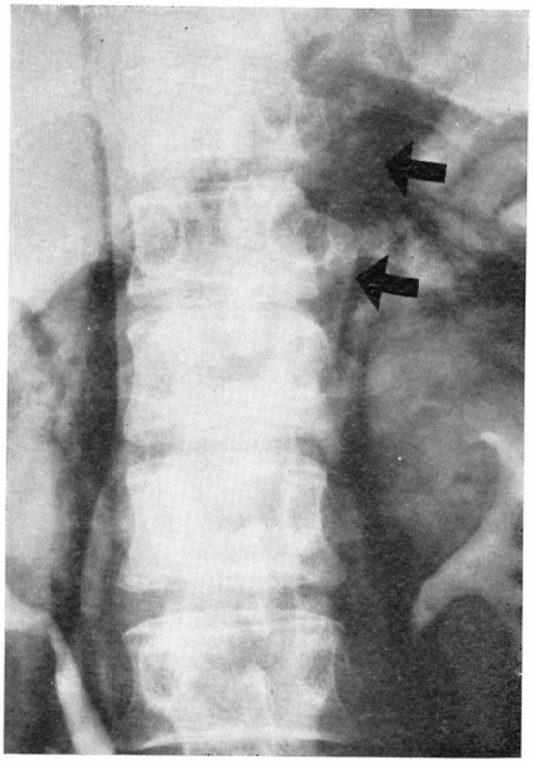

Fig. 8B

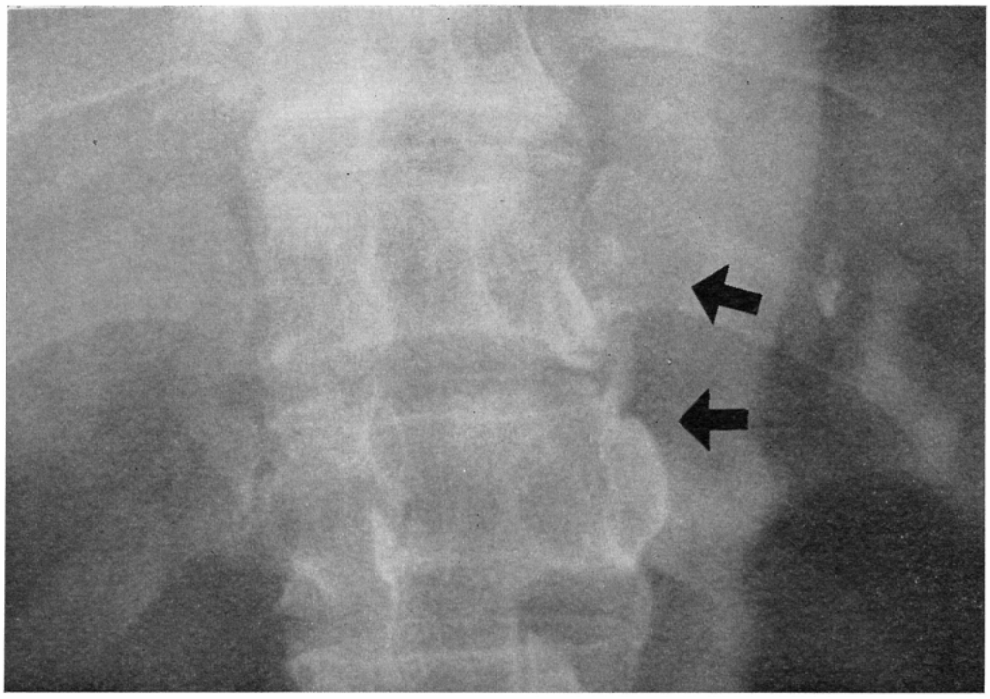

Fig. 9A

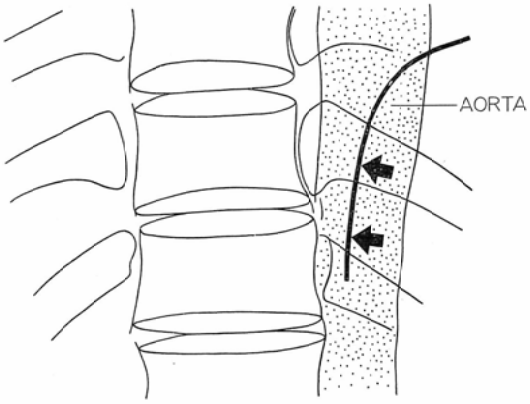

Fig. 9B

Case 4

A 54 year old male with hypertension for three years. A pneumoretroperitoneal study was performed to rule out a pheochromocytoma (Fig. 7). The superior portions of the medial aspect of the hemidiaphragms are seen bilaterally on the tomograms.

The Medial Aspect of the Hemidiaphragm and Tuberculosis of the Spine

Among the disease processes occuring adjacent to the medial aspect of the hemidiaphragms, tuber-

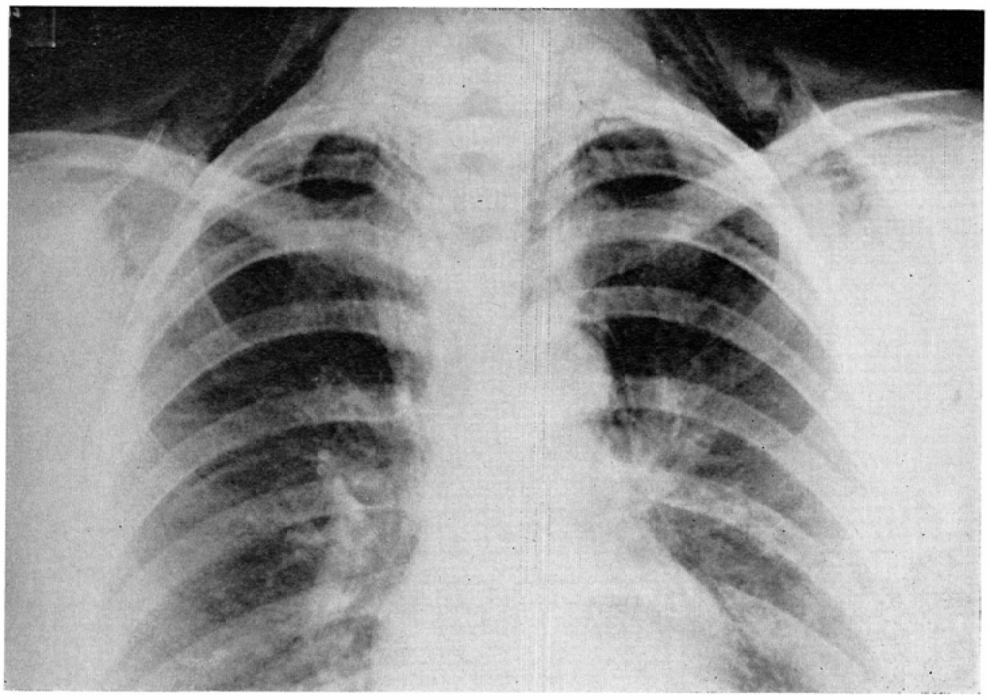

Fig. 10A

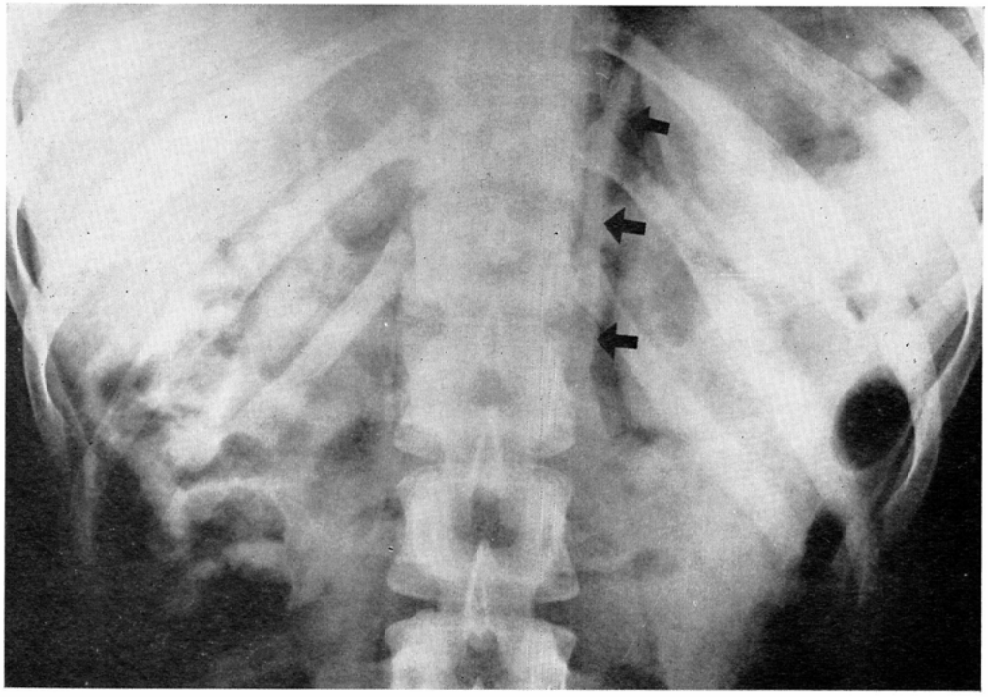

Fig. 10B

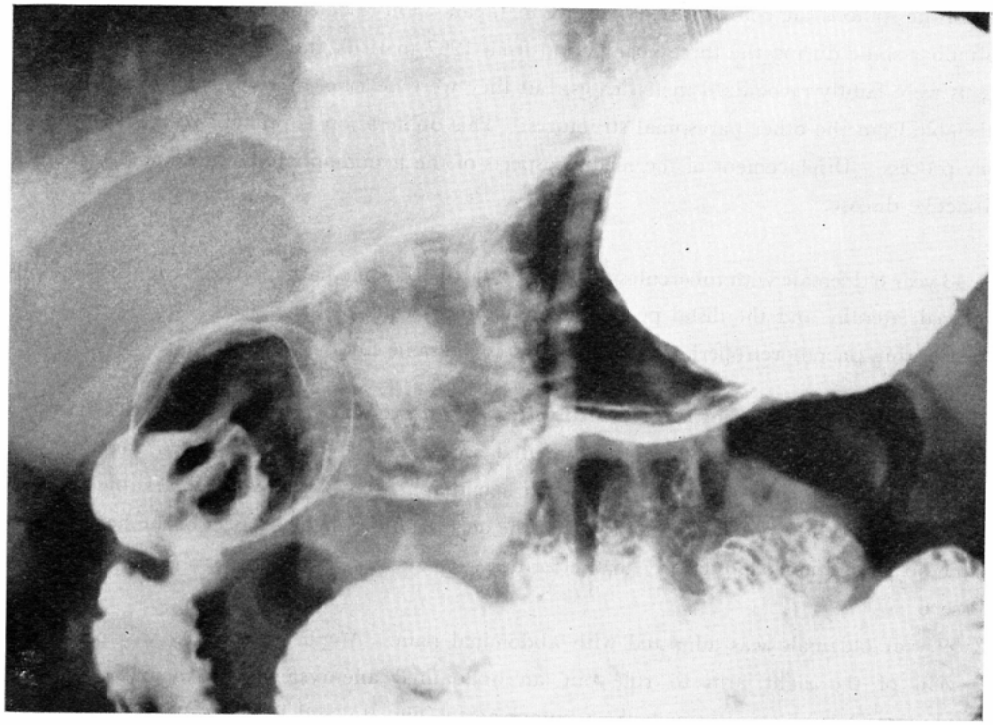

Fig. 10C

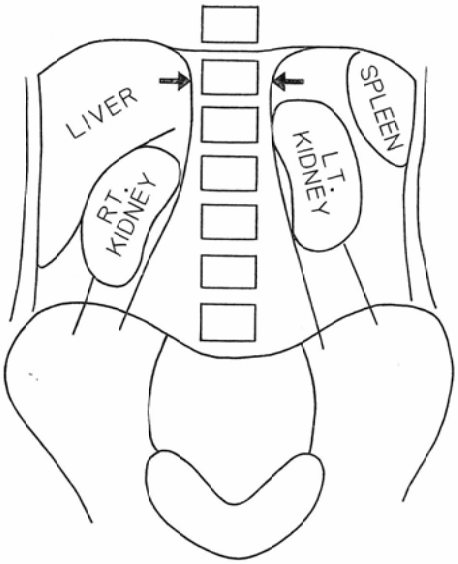

Fig. 11

culosis of the spine is the commonest, especially in Japan. On reviewing 17 cases of tuberculosis of the dorsolumbar spine during the three year period from 1967 to 1970, the medial aspects of the hemidiaphragms were faintly recognized in ten cases, but they were never clearly seen and were almost undistinguishable from the other paraspinal structures. This obliteration is probably related to the inflammatory process. Displacement of the medial aspects of the hemidiaphragm were noted in both active and inactive disease.

Case 5

A 43 year old female with tuberculosis of D9 and D10. The medial aspect of the left hemidiaphragm is displaced laterally and the distal portion is obliterated by the paraspinal abscess (Fig. 8A). A film obtained during pneumoretroperitoneal study reveals the same findings (Fig. 8B).

The Medial Aspect of the Hemidiaphragm and the Tortuous or Dilated Aorta

On reviewing thirteen aortograms, the medial aspects of the hemidiaphragms were seen in five cases. Displacement of the medial aspect of the hemidiaphragms was not as remarkable as expected. This is probably due to the relationship between the aorta and the medial aspect of the hemidiaphragm, the latter being positioned posteriorly to the former.

Case 6

A 59 year old male was admitted with abdominal pain. Angiocardiography was performed via basilic vein of the right arm to rule out an abdominal aneurysm. The medial aspect of the hemidiaphragms can be seen through the tortuous aorta (Fig. 9A and B).

Addendum

After the completion of this paper, we happened to have a case which showed the medial aspect of the left hemidiaphragm more clearly than any previous case. The patient was a 19 year old female who experienced motion sickness during an auto ride and subsequently vomited several times. Immediately after vomiting she experienced sudden sharp chest pain and was admitted to our hospital. Routine chest and flat plate of the abdomen revealed pneumomediastinum and subcutaneous emphysema (Fig. 10A), which gradually extended caudally along the spine. The medial aspect of the left hemidiaphragm is shown on the abdominal film with unusual clarity (Fig. 10B). It was more clearly defined on a film made during upper gastrointestinal series through the gas distended stomach (Fig. 10C).

Summary

Roentgenological anatomy of the medial aspect of the hemidiaphragm was described as were its changes in pathological conditions. It's recognition on abdominal film might be of some benefit in evaluating the patient with abdominal or spinal disease. We propose that medial aspects of the hemidiaphragms should be added on the conventional shematic drawings of abdominal films (Fig. 11).

Acknowledgments

Thomas J. Imray, M.D., and Kenneth H. Abbott II, M.D., Lt. Col. USAF M.C. for their kind suggestions, to Miss Noriko Ohtake and Miss Miki Aoyama for manuscription of this paper and to Mr. Syushin Ohuchi and Miss Tomoko Sato for making photographic prints.

Address For Correspondence

Yoshihiro Hiramatsu, M.D., Department of Radiology, Teikyo University School of Medicine, 2-11-1, Kaga, Itabashi-ku, Tokyo 173 Japan.

Legends for Figures

Fig. 1. Schematic diagram depicts the anatomical relationships between ligaments and crura.

Fig. 2. Autopsied case; Large arrows indicate pins in medial aspect of the hemidiaphragms. Small arrows indicate the pins in the crura.

Fig. 3A. Case 1; Thin opaque line is clearly seen in left upper quadrant along the spine. A faint line is also noted on the rihgt side.

Fig. 3B. Photographic magnification of Fig. 2A.

Fig. 3C. Case 1; Film obtained during intravenous urography again shows the lines clearly.

Fig. 4. Case 1; Nephrotomogram demonstrating the line to be continuous with the diaphragm.

Fig. 5. Case 2; Medial aspect of the left hemidiaphragm could be mistaken for one of the gastric folds.

Fig. 6A and 6B. Case 3; Prone film in a slight right anterior oblique projection shows the line clearly (5A), but it is not seen on the straight prone film (5B).

Fig. 7. Case 4; The medial aspects of the hemidiaphragms are well demonstrated on tomogram obtained as a part of pneumoretroperitoneal examination.

Fig. 8A. Case 5; The line (left hemidiaphragm) is displaced laterally and obliterated distally by a tuberculous paraspinal abscess.

Fig. 8B. Case 5; Pneumoretroperitoneal study shows the same finding as seen in the Fig. 7A.

Fig. 9A and 9B. Case 6; The line of the hemidiaphragm is faintly seen through the partially opacified aorta.

Fig. 10A. Pneumomediastinum and subcutaneous emphysema are noted on the chest film.

Fig. 10B. The medial aspect of the left hemidiaphragm is clearly seen on the abdominal film as outlined by the dissection of the air caudally.

Fig. 10C. Double contrast study of the upper gastrointestinal tract. The linear shadow of the left hemidiaphragm is well demonstrated through the gas distended stomach.

Fig. 11. Bilateral arrows on the schema show medial aspects of the hemidiaphragms.

References

1) Goss, C.M.: Gray's Anatomy, 28th edition, p. 416. Lea & Febiger, Philadelphia U.S.A. 1966.
2) Grant, J.C.B.: Grant's Atlas of Anatomy, 5th edition, The Williams & Wilkins Co., Baltimore, 1962.
3) Dumbar, D., Molnar, W., Beman, F.F., Marable, S.A.: Compression of the celiac trunk and abdominal angina, Am. J. Roentgenology. 95 (1965), 731–744.
4) Reuter, S.R.: Accentuation of Celian Compression by the median Arcuate Ligament of the Diaphragm During Deep Expiration, Radiology. 98 (1971), 561–564.
5) Schmidt, H.: Roentgen tomographisch-anatomischer Atlas, Gustav Fischer Verlag, Stuttgart, 1970.