Osaka University Knowledge Archive

Title	Esophageal Intramural Pseudodiverticulosis with Esophageal Cancer Improved by Target Rotation Irradiation : Case report
Author(s)	Naoi, Yutaka; Katayama, Hitoshi; Tomiyoshi, Hideki
Citation	日本医学放射線学会雑誌. 1997, 57(8), p. 526-527
Version Type	VoR
URL	https://hdl.handle.net/11094/18811
rights	
Note	

Osaka University Knowledge Archive : OUKA

https://ir.library.osaka-u.ac.jp/

Osaka University

症例報告

Esophageal Intramural Pseudodiverticulosis with Esophageal Cancer Improved by Target Rotation Irradiation: Case report

Yutaka Naoi, Hitoshi Katayama and Hideki Tomiyoshi

Department of Radiology, Juntendo University School of Medicine

Esophageal Intramural Pseudodiverticulosis with Esophageal Cancer Improved by Target Rotation Irradiation: Case report

Yutaka Naoi, Hitoshi Katayama and Hideki Tomiyoshi

Etiology of esophageal intramural pseudodiverticulosis is still unknown but several accompanying diseases have been reported, for example, reflux esophagitis, esophageal cancer, diabetes mellitus and so on. We have experienced a case of esophageal intramural pseudodiverticulosis with cancer improved by radiation therapy. In this case, there were esophageal cancer in the cervical esophagus, with intramural spreading in whole esophagus. This case was delivered irradiation to the entire esophagus by target rotation method. After irradiation, intramural pseudodiverticula, intramural spreading and primary site of esophageal cancer were improved. This is an interest case report that esophageal intramural pseudodiverticula with cancer was disappeared by radiation therapy.

Research Code No. : 511

Key words : *Radiation, Esophageal cancer, Intramural pseudodiverticulosis*

Received Jan. 16, 1996; revision accepted Apr. 23, 1997

Department of Radiology, Juntendo University School of Medicine

Introduction

We report a case of a patient with extensive esophageal cancer and esophageal intramural pseudodiverticulosis which was disappeared following radiation therapy. In this case, whole esophagus was involved with cancer. Therefore radiation was applied to the entire esophagus by the target rotation method. This is the first report to the best of our knowledge that intramural pseudodiverticulosis with esophageal cancer was disappeared by radiation therapy.

Case report

A 78 years-old japanese woman admitted with swallowing disturbance since a few months ago. She had no other major medical problem. Barium swallow revealed narrowing of cervical esophagus and multiple small outpouchings in the entire esophagus (Fig.1 lt side). Panendoscope demonstrated small elevated lesion in the cervical esophagus suggestive of esophageal cancer (Fig.2). Biopsy specimen revealed squamous cell carcinoma in this lesion. After Lugor's solution was applied to esophageal mucosa, multiple uncolored areas were appeared in entire esophagus. Biopsy specimen from these uncolored area revealed also squamous cell carcinoma.

Chemotherapy was performed by using CDDP and 5-FU. But intramural pseudodiverticula and narrowing were not improved after two courses of chemotherapy. One month after chemotherapy, radiation therapy were performed by Linac system with multi leaf collimator using 10MV X-ray. Since esophageal cancer was spreaded to the entire esophagus and this patients was elderly person, irradiation technique of target rotation method was selected (Fig.3). 60Gy was given in 30fraction/50days (2weeks split course). After irradiation, barium swallow showed improvement of narrowing of the esophagus and no intramural pseudodiverticula. (Fig.1 rt side). Biopsy specimens revealed no carcinoma cells. 6 months later, this patients has remained free of esophageal cancer and intramural pseudodiverticulosis.

Discussion

Since esophageal intramural pseudodiverticulosis (EIP) was first reported by Mendl[1] in 1960 as an abnormality which had radiological

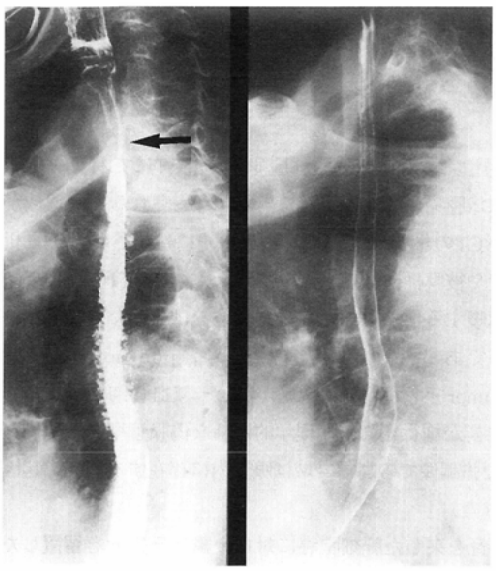

Fig.1　Lt side: Barium swallow before irradiation. There were multiple pseudodiverticula in the entire esophagus. Esophageal cancer was seen in the cervical esophagus (arrow).
Rt side: Barium swallow (double contrast method) after irradiation. Pseudodiverticula were disappeared com-

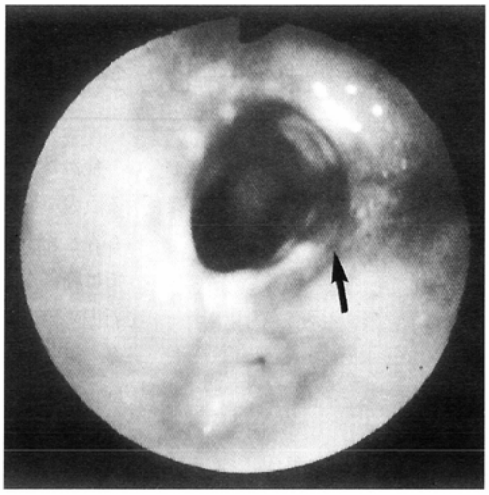

Fig.2　Endoscope demonstrate an elevated lesion in cervical esophagus characteristic of esophageal cancer (arrow).

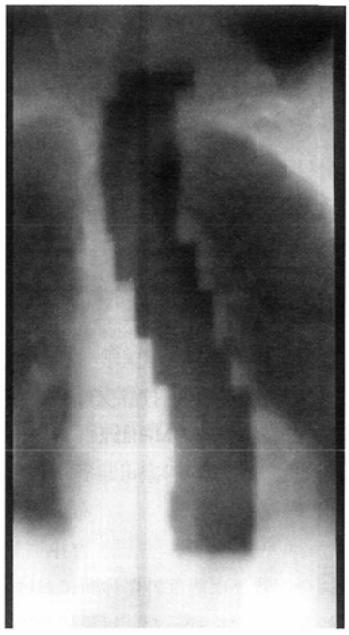

Fig.3 Linacography by target rotation irradiation using multi-leaf collimator.

findings similar to those of Rokitansky Aschoff sinuses of the gallbladder, some cases have been documented especially in Europe and America. Levine[2] detected this abnormality in 0.15% of 14,350 cases of barium swallow. EIP, however, is very rare condition in Japan[3], as there was a few case reports.

Unlike the usual diverticulosis, the dilated esophageal glands were not covered with a muscular layer of mucosa, therefore this disease was designated as pseudodiverticulosis . Although the causes of dilated esophageal glands remains unknown, two hypotheses have been proposed [4]. One suggests that the excretory duct of an esophageal gland is filled with, or obstructed by, ablated esophageal epithelia or some inflammatory substances, which then results in dilatation. The other theory suggests that, the orifice of the excretory duct is compressed and contracted by fibrosis or secondary to chronic esophagitis. These hypotheses are supported by the fact of high incidences of intramural pseudodiverticulosis in patients with reflux esophagitis, and diabetes-related candidiasis, or alcholics. Particularly, intramural pseudodiverticulosis is frequently complicated by esophageal hiatal hernia, and Cho et al [5].noticed the hernia in 18 of 45 patients with intramural pseudodiverticulosis.

On the other hand, this disease is also associated with herpetic oesophagitis, esophageal carcinoma, post-irradiation, Wegener's granulomatosis, steroid administration, esophageal web and AIDS[2].

Radiological findings of barium meal study were characteristic enough to lead to definite diagnosis. The barium study reveals many microdiverticulum-like outpouchings 1 to 3 mm in diameter in the esophageal wall. Stenoses are observed in almost all cases, ranged from several centimeters to two-thirds of length of the esophagus. Many of the diverticulum-like outpouching were segmental, and most frequently occurred in the lower esophagus[2]. In order to the dilated esophageal glands are filled with viscous mucus, EIP were shown on esophagogram after several or as many as 20 times or more barium swallowings in some cases[4]. This fact suggests that some cases may possibly be failed to be defined on the conventional barium meal study.

Endoscopic examination of EIP shows acute or chronic esophagitis with stenosis in the corresponding region of pseudodiverticulum in 60 to 80% of the cases. Clinicians should understand that some patients have no endoscopic abnormalities. Bruhlmann[4] reported no anomalies in 6 of the 46 patients (13%) with intramural pseudodiverticulosis who were undergone endoscopy. Biopsy also reveals acute or chronic esophagitis in many of the cases, and it hardly demonstrated dilated glands[3]. Biopsy also reveals inflammatory change and fibrosis.

This case showed intramural pseudodiverticula of the entire esophagus with diffuse intramural spreading from cervical esophageal cancer. In this case intramural pseudodiverticula were disappeared completely by external radiation therapy. This fact is suggestive of esophageal glands being obstructed by intramural spreading of esophageal cancer.

References

1) Mendl K, Mckay JM, Tanner CH: Intramural diverticulosis of the esophagus and Rokitansky-Ascoff sinuses in the Gall-Bladder. Br J Radiol 33: 496-501, 1960
2) Levine M.S, Moolten DN, Herlinger H,et al: Esophageal intramural pseudodiverticulosis: a reevaluation. AJR 47: 1165-1170, 1986
3) Naoi Y, Shirakata A, Muraoka M, et al: A case report of esophageal intramural pseudodiverticulosis. Jpn J Clin Radiol 35: 305-308, 1990
4) Bruhlmann WF, Zollikofer CL, Maranta E, et al: Intramural Pseudo diverticulosis of the esophagus; report of seven cases and literature review. Gastrintest Radiol 6: 199-208, 1981
5) Cho SR, Sanders MM, Turner MA, et al: Esophageal intramural pseudodiverticulosis. Gastrointest Radiol 6: 6-16, 1981