Osaka University Knowledge Archive

Title	Clinical use of the so-called bronchodilator in bronchography (Pharmaco-radiologic explaration of the bronchopulmonary systems chapter 1)
Author(s)	斎藤, 達雄; 清水, 浩; 小倉, 敏郎 他
Citation	日本医学放射線学会雑誌. 1962, 21(10), p. 954-964
Version Type	VoR
URL	https://hdl.handle.net/11094/18851
rights	
Note	

Osaka University Knowledge Archive : OUKA

https://ir.library.osaka-u.ac.jp/

Osaka University

Pharmaco-radiologic Exploration of the Bronchopulmonary Systems
Chapter I
"Clinical use of the so-called Bronchodilator in Bronchography"

by

Tatsuo Saitō, Hiroshi Shimizu, Toshiro Ogura and Yuichi Inagaki

From the Department of Radiology, Nippon Medical School, Tokyo, Japan
(Director: Prof. T. Saitō)

The summary of this article was reported at the 20th general meeting of the Japanese Soceity of Medical Radiology (Osaka).

気管枝—肺系に対する薬理—X 線学的研究
(第1篇) 気管枝造影に於ける所謂気管枝拡張剤の臨床的効用に就いて

斎藤達雄 清水 浩
小倉敏郎 稲垣悠一

(昭和36年12月17日受付)

気管枝造影法により気管枝-肺系の病態を正確に把握するためには従来の各種造影術式を十分駆使して造影写眞を判読しなければならないが，更に所謂気管拡張剤を投与して気管枝像の変化を追求する薬理-X線学的方法を施行する必要性が痛感された．この方法の臨床上意義ある適応としては次の如き場合が考えられ，機能的変化としての異常所見が器質的変化から除外し得よう．

1) 造影剤の進行遅延乃至造影不全
2) 気管枝の各種の狭縮像を示せる場合
3) 気管枝に辺縁不正，拡張などの変形を示せる場合
4) 気管枝内の造影が不均等で，分泌物，気胞などの存在が考えられる場合
5) 選択造影法の場合

気管枝拡張剤の投与は又，咳嗽反射を抑制する傾向があるので，気管枝像の比較的長時間の経過追求が可能という長所がある．

(本研究は文部省科学研究費の援助を受けた．)

Content

Ⅰ. Introduction
Ⅱ. Method of Observation
Ⅲ. Reviews of the Cases
Ⅳ. Discussion

1. Evaluation in using for the uncompletly pictured lungfield
2. Effective value for the bronchospastic picture
3. Effective value for the drawing-ability of the lungfield involved
4. Effective value for the deformative pictures of the bronchi
5. Effective value for the differential diagnosis
V. Summary
References

I. Introduction

It is hardly necessary to mention here of an important role of the bronchography in diagnosis of bronchopulmonary diseases; in recent years, however, it has been reported that the vitalradiographical findings and the pathological-anatomical findings of the autopsy or the specimens do not always coincide with each other[1)2)3)4)5)]. The differences are due to the following factors:

1) The vital-functional reactions of the bronchi may be brought about from the artificial procedures, "bronchography,—especially selective bronchography".

2) In bronchograms, the abnormal aspects of the bronchial functions may be present as various morphological changes.

3) In addition to this, there is a certain limit in drawing out pathological bronchi involved in bronchography.

These points have been proved by comparative observations of general and selective bronchography[6)], or, the bronchograms taken during inspiration and expiration[7)8)].

For the diagnostics of bronchopulmonary diseases, exact reproductions of pathological findings in the films is required, and also reading of various functional pathological features which rarely show themselves as pathomorphological findings, should never be neglected. For this purpose, various bronchographic observations above mentioned[6)7)8)] are necessary, and also, application of bronchodrugs physico-pharmacologically for diagnostic use, may be taken into consideration.

Radiological application of bronchodrugs has become more feasible due to the improvement of contrast media and radiographic technique; there is time enough for phothographing. Thus, the authors have obtained some interesting knowledge: clinical value of the bronchodrug upon radiographic diagnosis and the pharmacologic process of the drug radiographically observed.

In this capter, cases (that show abnormal pictures due to unorganic changes of the bronchi) with effective results with the use of so-called bronchodilator, will be reviewed and discussed.

II. Method of Observation

In diagnosing the bronchopulmonary diseases with bronchography in our clinic, firstly the so-called "general bronchography" is carried out, by which the contrast medium [60% Urokolin Oily Suspension—Daiichi Seiyaku (Tokyo)—] is introduced by means of

intubation of the Nelaton's catheter; this makes "out-look radiography" to diagnose a wide lungfield; if necessary, the so-called "selective bronchography" in which the contrast medium is administered through the deeply introduced Métras' catheter; this makes "specific radiography" to diagnose a limited lungfield. In combination of these procedures, many favorable results have been obtained[6], however, even after those method are all tried, we may sometimes fail to draw out satisfactory features of the bronchi and the lungfield involved.

Under these circumstances, we obtained recognizable effect by using bronchodilator such as Epinephrine and Aminophyllin etc. which is reported as follows.

III. Reviews of the Cases

Case 1. male, worker, 24 years old. He has been complaining of slight cough since a month before. As his chest X-ray showed no particular abnormal findings except a small cicatrix in the lung apex, general bronchography was performed for further accurate examination.

Upon bronchography (Fig. 1a), the progression of the contrast medium was so delayed that the drawing of the lower lobe field was not showed even 5 minutes after, though the upper lobe bronchi were immidiatly photographed. Upon the subcutaneous injection of Epinephrin (×1000) 0.5 cc, it appeared drawed, and following the course of the times, length and width of the bronchi became increased. As there is no particular shadow in the lungfield, it is interpreted that the bronchographic findings without administration of the drug shows functional bronchial changes as a symptom of the bronchitis.

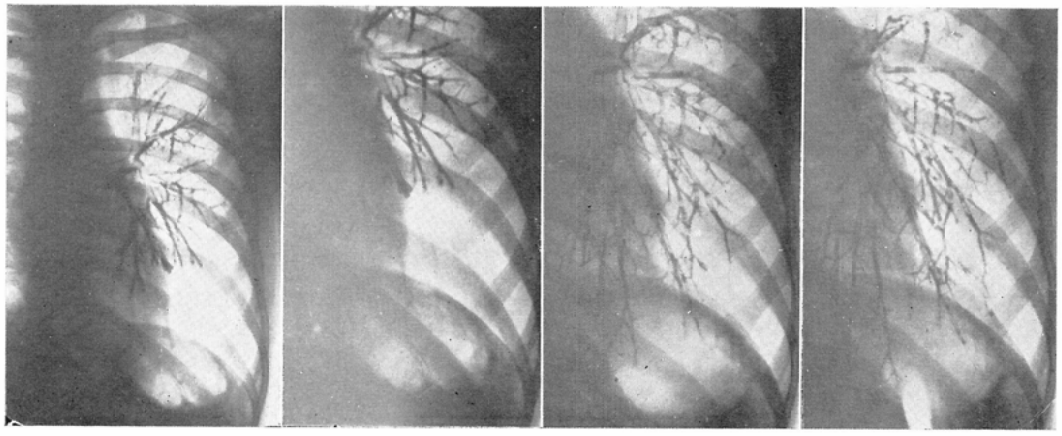

a b c d

Fig. 1. Case 1.

a: Progression of the contrast medium was so delayed that the drawing of the lower lobe field was uncompletely showed.

b: Enlarged view of mid-and low-zones.

c: By the subcutaneous injection of the Epinephrin, it became drawed.

d: Length and width of the bronchi became incrersed after 10 minutes.

Case 2. male, company employe, aged 38. This is a case with fibro-cicatric lesions in the lungapex and chronic bronchitis was confirmed by bronchography. Routine film (Fig. 2a) shows no peculiar shadow except fibro-cicatric lesions of the both apexes. In the right general bronchogram, the dilated segment-bronchi of the upper lobe are massing and ascending, but, in the further peripheric bronchi, the passage of the contrast medium is not easily showed with stagnant, it flows partly into the opposite left bronchus, while the trunk of the middle and lower lobe bronchi are cutting—"absent bronchus (Huizinga)" (Fig, 2b). Then, after the intravenous injection of the Neophyllin(Eisai-Tokyo-) 0.25 g-Theophylline-ethylendiamine-, the progress of the medium into the peripheral field began immediately (Fig 2c).

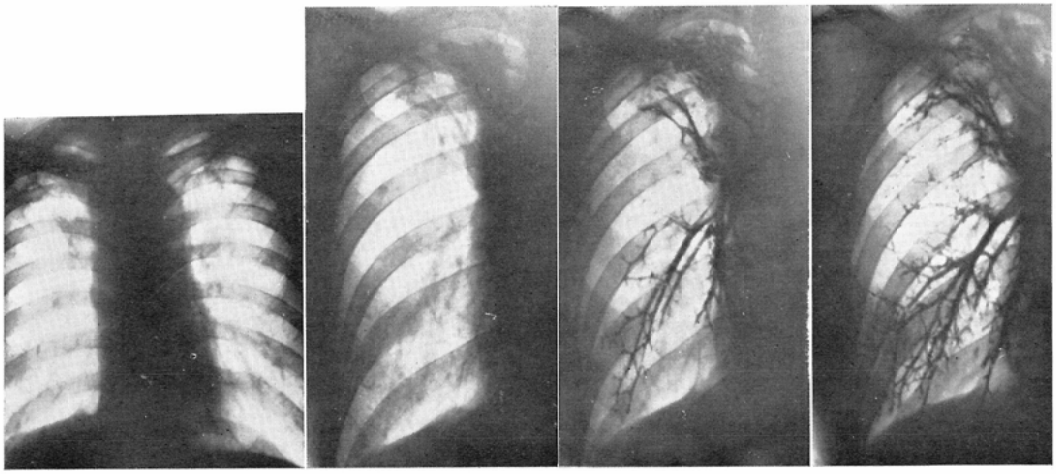

a b c d

Fig. 2. Case 2.

a. Routine film shows no peculiar shadow except fibro-cicatric lesions of the both apexes.
b. Dilated segmentbronchi of the upper lobe are massing and ascending; in the more lower bronchi, the progress of the contrast medium is limited.
c. After the intravenous injection of Neophylline the progression began immediately. Varions spastic findings are showed.
d. Bronchography was almost completed, Spastic finding relaxed after 5 minutes.

The bronchograms taken at this time and 5 minutes later, were almost perfect, following the course of the time, the spastic graphic finding became relaxed (Fig 2d). According to the observation of these courses, this case may be diagnosed as "spastic bronchitis" evoked by broncho-drug. In other words, the so-called "absent bronchus" of the middle and lower lobe bronchi in the bronchogram is a sort of spastic finding and these bronchi photographed with drugadministration, firstly, show narrowed bronchial-figure and number of bifurcated branches deminishes because of spasm, as time elapses, these constriction is relaxed.

The drawn bronchi do not contain the secretory subtance, air-bubble and, bronchial

wall is smooth ; here, it can be under stood that these graphic findings are a typical symptom of spastic bronchitis.

Case 3. male, campany employe, aged 36. This is a case in whom cavernocaseous changes pressent in the right lung-field (Fig 3a), and according to the left bronchography, peripheral bronchi of B_9 was drawed completely, but, peripheral bronchial walls were irregular and partly dilated (Fig 3b). A selective bronchography of B_9 for an exact

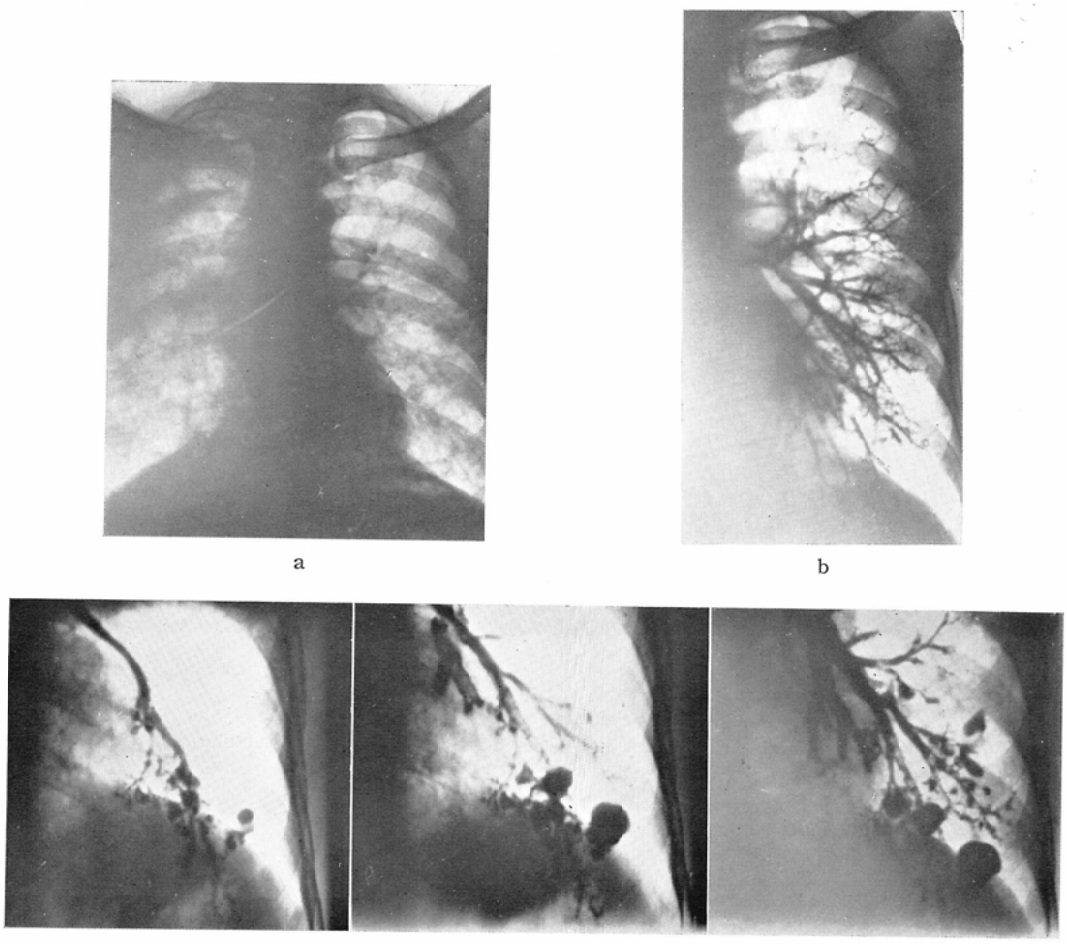

a b c d e

Fig. 3. Case 3.

a: Routine film shows cavernocaseous changes of the right lungfield and the complex breaking of the lung marking of the left lower field.

b: General bronchogram of the left lung shows irregularity of the peripheral bronchial walls of B_9

c: Selective bronchogram of B_9 shows a small cavity and a few branches.

d: This shows a few cavities and spastic branches increased in number, after the injection of Neophyllin M.

e: The bronchogram of B_9 with cavities was established after 15 minutes.

examination was made, as a routine film showed complex breaking of the left lung marking. As first, only a branch of the B_9 and a small cavity was drawn (Fig 3c), so, the intravenous injection of Neophillin M-(Eisai) 0.3 g(-Dihydroxyprophyl-theophilline) was made, and 5 and 15 minutes later, branches-numbers of the bronchi increased and a few cavities was pictured gradually. (The branches-number in this bronchogram, however, is less than that in the general bronchogram!) (Fig 3 d,e). During the procedure, seizure of

a

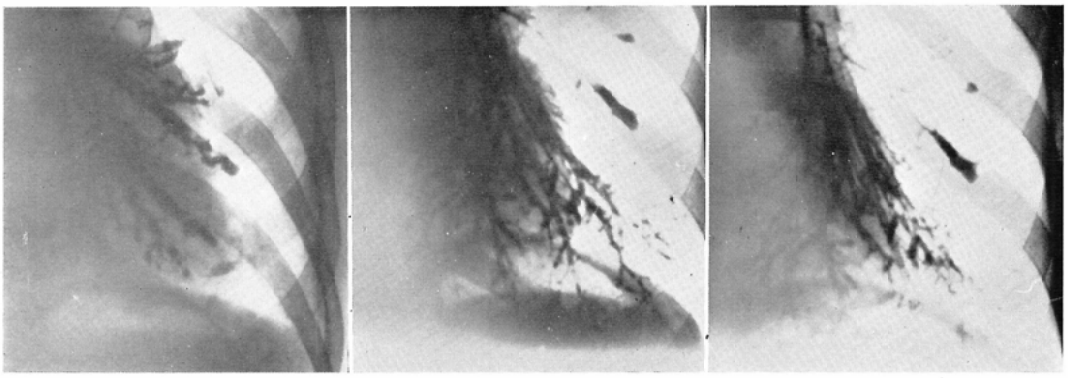

b c d

Fig. 4. Case 4.

a: Left general bronchogram shows bronchiectatic findings of all the bronchi.

b: Enlarged view of lower lobe bronchus. Irregularity or dilatation of the bronchial walls is seen

c: Bronchogram made after injection of epinephrine shows normalzation of the bronchial wall with branchesnumber increased except B_8

d: Length and width of the bronchi increased after 5 minutes.

cough was absent. The case makes a demonstrable case implying that the bronchial branches in numbers are less due to bronchial spasm in the selective bronchography than in the general bronchography, and that it is more in detail pictured by administration of the drug, and cavities too are showed. It is reviewed that a part of the bronchi which showed bronchial shrinkage, was relaxed by drug-administration.

Case 4. male, company employe, aged 31. This is a case with cavernoinfiltrative lesions of the upper lobe, and the findings of deformative-dilative bronchitis of the lower

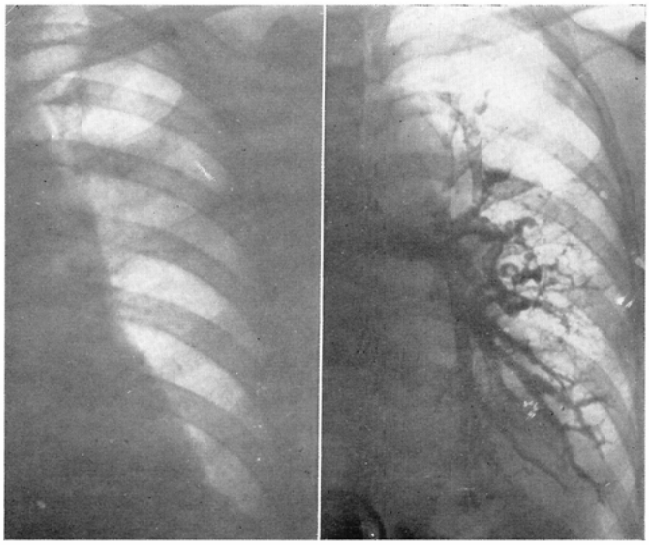

a b

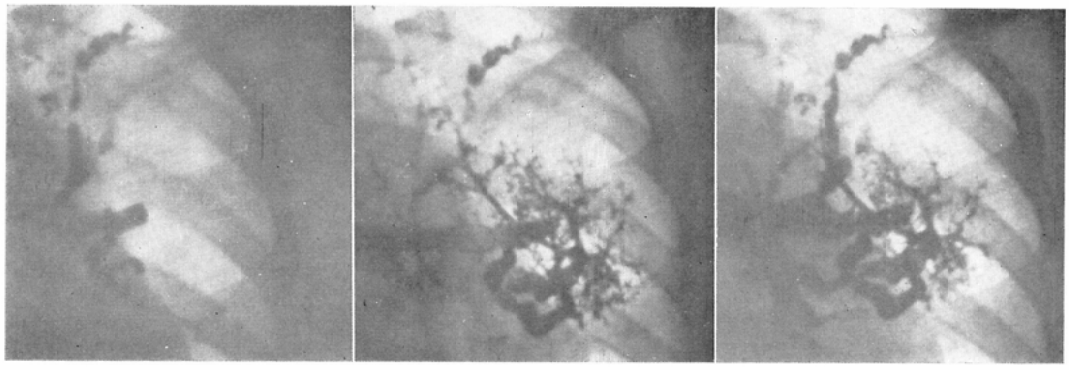

c d e

Fig. 5. Case 5.

a: Routine film shows infiltrativ-caseous lesions of the left upper field.

b: General bronchogram shows the dilatation and stenosis of the regional bronchus.

c: Selective bronchogram of B_3 shows narrow pictures and less branching in the parts.

d et e: By Neophyllin-injection Peripheral foliages was drawed.

Unchangeable figures are seen in the all bronchograms.

lobe were observed in general bronchography (Fig 4 a,b). The subcutaneous injection of 0.1% Epinephrine 0.3 cc brought about deformatine pictures of the B_9 and B_{10} as that the bronchial walls became smooth, and the dilated pictures disappeared (Fig. 4 c). Following the course of time, the number of branching increased and peripheral bronchi became drawed and the abnormal pictures returned to normal (Fig 4 d). This case indicates that bronchodilator tend to normalize the pathological-deformative bronchial findings, subsequently it is assumed that these abnormal pcitures of the bronchi are the sequela of non-organic lesions.

Case 5. female, housewife, aged 32. This is a tuberculous case with infiltrative caseous lesions of the left S_3 (Fig. 5 a) in general bronchography (Fig. 5 b) the regional bronchus shows the pictures of dilatation and stenosis. Whereas, selective bronchography of the B_3 was made (Fig. 5 c). In this bronchogram, B_3 party shows similar finding to that of the general bronchogram, however, in contrast to it, other part of it pressents narrow pictures and the less branching.

When Neophillin M (Eisai) 0.3 g was administered, peripheral bronchial foliages in incompletely graphed lungfield was drawed.

Unchangeable bronchial figures are seen in all bronchograms including general bronchogram; however, it is to be interpreted that these changes are ascribed to the organic lesions, since the branches are located in the caseous lesion.

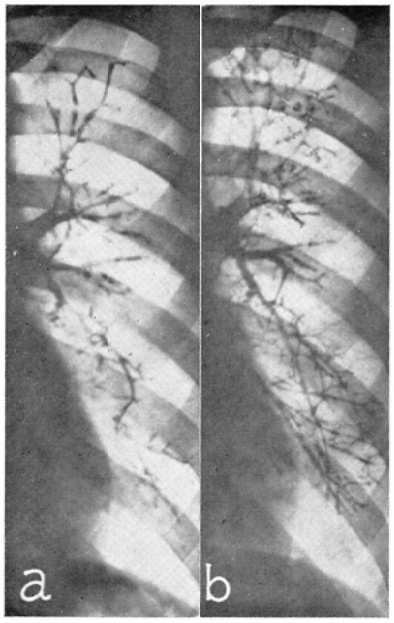

Fig. 6. Case 6.
a: Left general bronchogram shows spastic findings of the left upper lobe bronchus.
b: By injection of the Neophyllin, spastic pictures were fairly relaxed.

Case 6. male, company employe, aged 26. In the left general bronchography of this patient with such a symptom as asthmatic bronchitis, namely, in-and-out wheezing in the chest, the bronchi show generally fine-narrow shrinking figures, and bifurcation of the bronchial-branch shows constricting-the so-called "Strangulation (Di Rienzo)" (Fig. 6 a). After the intravenous injection of the Neophillin (Eisai) 0.25 g, these spastic pictures were fairly well relaxed (Fig 6 b).

IV. Discussion

1. Evaluatiou in using for the uncompletly pictured lungfield

In general bronchogram, uncomplete picturing of the lungfield is caused by the diminution of the inspiratory suck (i.v. pulmonary emphysem, lungfield with lesions) or by the non-organic changes (i.v. bronchospasm, secretion, broncho-paralysis etc.) of the bronchus, unless there is organic changes that obstruct the bronchial lumen, or technical errors. The delayed or uncomplete picturing in case 1 is due to functional change of the bronchi; because, massive lesion is nothining in the lungfield uncompletely pictured, bronchogram before and after Epinephrin-injection does not show the fleck-pictures of secret, airbubble, irregular figures of the bronchial wall, and bronchial picture shows a normal beautiful peripheral foliage.

Further, according to the large respiratory change of the volume of the lower lobe, lungemphysem can be neglected. From this case it is confirmed that the bronchodilator is effective for the investigating lungfield uncompletly pictured.

2. Effective value for the bronchospastic picture

Several investigators[9)13)] using the drugs in bronchographic diagnosis, have administered it in occasion of bronchospasm occured as a symptom of bronchitis. Schinz described that spasm was relaxed after inhalation of amylnitrit, administration of epinephrine and injection of asthmolysin or ephedrine in the spastic bronchitis in which bronchial trunk is cutting and branches are not clearly pictured. Case 2 is chronic bronchitis with pulmonary tuberculosis, and its pathologic state may be clearly understood by drugadministration.

In the so-called bronchospastic figures, there is "absent bronchus (Huizinga)" in which bronchial trunk is sometimes cutting and bronchial branches sometimes absent, and also fine-threading of bronchi or, shrinking of the bifurcation of the branches "the so-called Strangulation—Di Rienzo"—as case 3 and 6 are observed. However, such functional conditions must be diagnosed only after release of spasm by the use of the bronchodilator.

3. Effective value for the drawingability of the lungfield involved

As bronchial pictures in the general bronchogram are mostly made due to inspiratory suck of the peripheral lungfield, normal lungfield is easily drawed to peripheral branches, but, if there is the lesions, the peripheral branches of the regional bronchus are difficultly drawed, because of the decreased suction of the parts of the lungfield with lesions, then, the cavity comunicating with bronchus suck in hardly contrast medium.

Consequently, selective bronchography through the Metrás sound is nessesary, and by

using of this technique pathologic small bronchi, or cavities are easily pictured.

Even though this technique is taken, however, bronchography may not be made completly. In such occasions, bronchodilator must be used as in case 3. Thus, broncho-cavitary state is clearly demonstrated.

It is due to spasm that firstly bronchography is resisted, this is understood according to show the dilative changes of the bronchial pictures (dilatation, Obstruction) of parts of the bronchi are due to artificial stimulus for the bronchi in the selective bronchography, differing from the general bronchography.

It is proved that bronchofunctional changes are reversible by drug, and that these deformative pictures are relaxed by Neophyllin-injection.

4. Effective value for the deformative pictures of the bronchi

The form-changes of the bronchial figures are divided into two main classes, that is, obstruction or stenosis of the lumen and irregularity of the wall or dilatation of the lumen. As functional significations of the former was discussed, the following will be discussed of the latter. Generally speaking, irregularity or dilatation of the bronchial figure immediately tends to be interpreted as pathologic-anatomic changes (infiltration, necrosis, erosion, ulcer, dilatation etc.) of the bronchial wall. Thus, such a case as case 4 tends to be diagnosed as cylindrical bronchiectasis of the lower lobe.

However, bronchial wall becomes smooth, dilatative finding disappears, lumen rather decreases, branchesnumbers increase, and almost normal peripheral foliage is formed, except B_8, by the administration of the drug. These changes are caused by the evaculation of the mucus and air-bubble from the brochi, and also normalization of the functional changes is caused by drug-administration.

It is interesting that the lumen of the dilatative bronchi decreases by drugadministration but, this phenomenon will be discussed in other chapter.

In any way, the bronchodilator have tendency to normalize functional changes of the bronchi.

5. Effective value for the differential diagnosis

It is established as before mentioned that various bronchial pictures changeable by the so-called bronchodilator are due to non-organic pathologic changes of the bronchial systems.

Bronchial pictures unchangeable by the drug can not always be determined as organic changes. However, according to general bronchography which gives the least outward stimulus, the normal lung shows beautiful bronchial foliages and is hardly mistaken for organic changes. Whereas, the fields including lesions is tend to be drawed incompletely.

Bronchographic pictures of these field do not show pathologic changes. Thus, compressions-selective bronchography is nessesary to draw the field including lesions, but this technique tends to produce stimulative-spastic change of the bronchi. Accordingly, abnormal pictures unchangeable by both bronchographic technique io largely due to organic change, and much more so, if there is a picture unchangeable in anywhere by drug-administration. It is understood that the case 5 presents caseous change of S_3, and re-

gional bronchus seems to show severe changes, in the parts of the bronchi, the pathologic pictures unchangeable by general and selective bronchography and may be due to organic changes whereas, bronchographic pictures of normal bronchi and parts of the bronchi change their morphologic figures by various bronchographic techniques.

V. Summary

In order to know exactly the pathologic state of bronchopulmonary systems, bronchgram must be interpreted with sufficient use of the various old graphic techniques, and also the necessity of pharmaco-radiographic technique by which one can throughly investigate bronchial changes due to the drug-administration, was kneely felt required.

Clinical indication of the pharmacoradiographic technique is as follows, and, various photographic pictures as functional changes may be neglected from the organic pathologic changes:

1) uncomplet, or delayed picturing,
2) various shrinkage of the bronchial lumens,
3) deformation such as irregularity, dilatation etc. of the bronchi,
4) intrabronchial picturing is of uniform, and, there may be mucus, air-bubble etc. in it,
5) on the selective bronchography.

As bronchodilator tends to supress the coughreflex, we can investigate bronchial figures for relatively long time. Bronchodilator, however, does not always act on the bronchi in the similar way, and conculsion of it is left for the future studies.

References

1) Buckles. M. et Potts, W.: Pulmonary tuberculosis with histopathologic correlation in 82 resections, Am. Rev. Tub., 64 : 394, 1951. — 2) Renault, P. et al.: La tuberculose des bronches, Vigot, 1954. — 3) Olson, D. et al.: Bronchial disease in lung resected for pulmonary tuberculosis, Am. Rev. Tub., 68 : 657, 1953. — 4) Ito F. et al.: The value of bronchofomography, Jap. Thoracic Surg., 10 : 301, 1957. —5) Kubo, K.: Radiographic finding of chest, J.J. A. T.S., 2 : 425, 1954. —6) Ogura, T.: The comparative observation of general and selective bronchography, The Jap. J. of Chest diseases, 19 : 433, 1960. — 7) Ogura, T.: Bronchographic studies on respiratory movement in the dispositions of the parts, Nippon acta radiologica, 18 : 425, 1953. —8) Ogura, T.: Bronchographic studies on respiratory changes of bronchus in stages on inspiration and expiration, Recent advances in tuberculosis research, 27 : 195, 1954. —9) Schinz, H. et al.: Lehrbuch d. Röntgendiagnostik, 5 Liff., Georg Thieme, Stuttgart, 1952. —10) Huizinga, E. et al.: Bronchygraphy, Van Gorcum, Assen, 1949. —11) Di Rienzo: Radiologic exploration of bronchus, C.C Thomas, 1949. — 12) Bariety, M. et al.: La trachée et les bronches, Masson et Cie, 1951. —13) Métras, H. et Charpin, J.: La cathéterisme bronchique, Vigot Fréres, Paris, 1953.