Osaka University Knowledge Archive

Title	Malignant X-ray findings of primary bone tumor
Author(s)	西岡, 清春; 松山, 正也
Citation	日本医学放射線学会雑誌. 1971, 31(9), p. 997-1006
Version Type	VoR
URL	https://hdl.handle.net/11094/20197
rights	
Note	

Osaka University Knowledge Archive : OUKA

https://ir.library.osaka-u.ac.jp/

Osaka University

Malignant X-ray findings of primary bone tumor

By

Kiyoharu Nishioka, M.D. and Seiya Matsuyama, M.D.

Department of Diagnostic Radiology, School of Medicine, Keio University, Tokyo

Research Code No: 505

Key Words: Primary Bone Tumor, Malignancy

原発性骨腫瘍の悪性X線所見

慶応大学放射線診断部

西岡清春　松山正也

(昭和46年8月16日受付)

過去10年間に経験した165例の原発性骨腫瘍について，そのX線所見を検討し，最も問題となる良性と悪性所見の鑑別について報告した．

X線像における悪性の判定として，1．発生部位について，2．形，輪郭，辺縁の所見について，3　骨皮質の破壊所見について，4．骨膜反応について，5．軟部陰影について，6．骨萎縮について，7．骨腫瘍のX線濃度について，以上の7項目を分析検討した．

We have experienced 165 cases of primary bone tumor during the past 10 years without special effort. Consequently, this disease is not a very common disease.

Table 1 shows the classification of bone tumor in the 165 cases. Osteochondroma, chondroma, chondrosarcoma, osteoma, osteogenic sarcoma, giant cell tumor, plasmocytoma, leukemia, neurofibroma, bone cyst and fibrous dysplasia were found rather frequently. Among the 165 cases, there were 51 cases of malignant bone tumor, 24 cases of semimalignant bone tumor, and 90 cases of benign lesion.

In order to understand the site of frequent occurrence of bone tumor and frequent age of onset, the site of presence of abundant tumor cells acting as the origin and the time of hyperfunction of these cells should be known. Table 2 summarizes the age of onset of main bone tumors and predominant sex. The predominant age corresponds with the period of the highest function of the tumor cells acting as the origin.

Fig. 1 shows the site of occurrence of the tumor in a long bone, corresponding to the site of abundance of the tumor cells acting as the origin. The site of occurrence of giant cell-, chondro-, osteo-, fibro-, and round cell group is thus regulated.

1. Judgement of malignancy in X-ray picture

Bone tumors are classified into parosteal, periosteal, cortical, eccentric cancellous, central cancellous, and medullary varieties according to their location. In each site, both benign and malignant

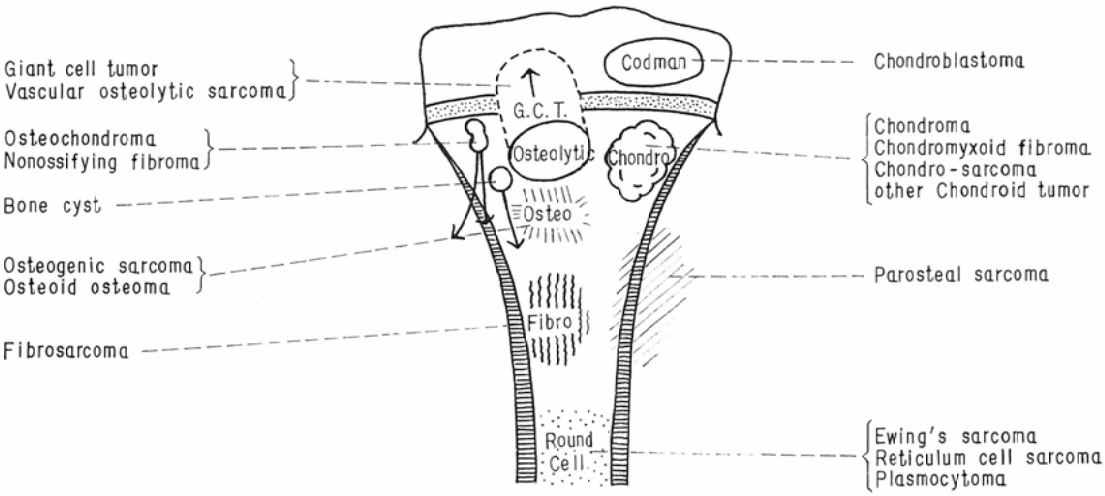

Fig. 1. Original location of bone tumors

Fig. 2. 12 year old female Multiple cartilaginous exostosis occurring from the 4th rib.

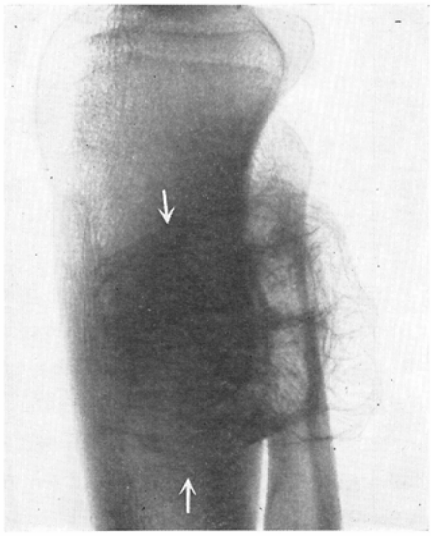

Fig. 3. 17 year old female Shows malignant osteochondroma from tibia.

bone tumors may develop. Among these, parosteal tumor is frequently malignant even if benign-appearing X-ray picture is obtained. Osteochondroma is the most frequently encountered among bone tumors. In the X-ray picture of osteochondroma, occurrence of irregular ossification and bone dissolution within a short period followed by enlargement suggests malignant change. Fig. 2 shows multiple exostosis occurring from the 4th rib of a 12 year old female, shown to be benign histologically. Fig. 3 shows osteochondroma in a 17 year old female with malignant transformation.

As representative parosteal tumors, osteochondroma, parosteal osteoma, parosteal osteogenic sar-

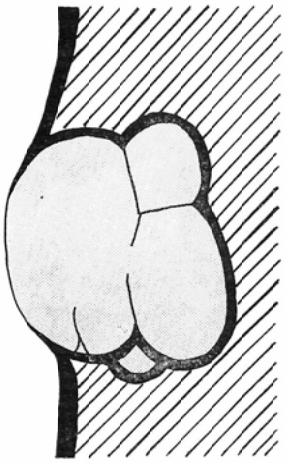

Fig. 4. Cystic, Loculated, honey-comb rarefaction. Enchondroma, Ecchondroma, Chondroblastoma, Chondromyxoid fibroma, Non-ossifying fibroma, Giantcell tumor, Hemangioma, Lipoma, Bone Cyst, Aneurysmal bone cyst, Fibrous dysplasia, Myxoma, etc.

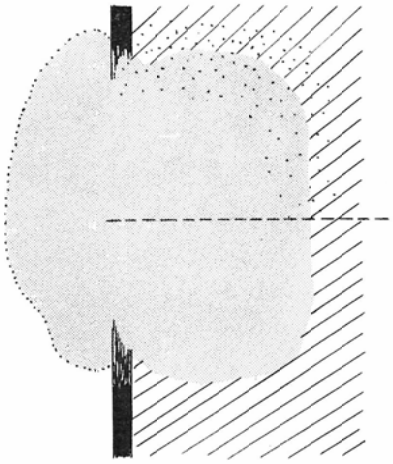

Fig. 5. Unsharp or osteolytic margin. Chondrosarcoma, Osteogenic sarcoma, Fibrosarcoma, Neurosarcoma, Chondroma, Liposarcoma, Xanthoma, Myxosarcoma, Ewing's Sarcoma, Plasmocytoma, Leukemia, Reticulum cell sarcoma, Metastatic bone tumor, etc.

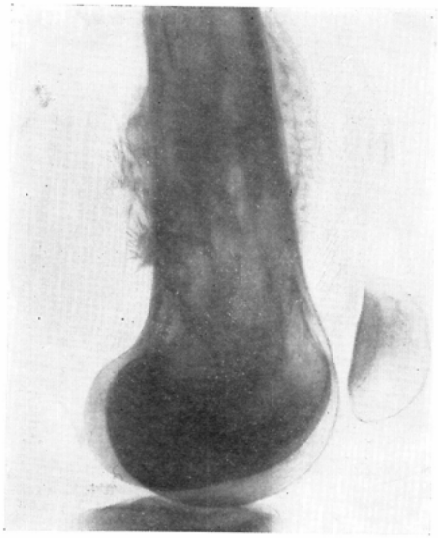

Fig. 6. 36 year old female Osteogenic sarcoma with mixed osteosclerotic and osteolytic lesions, border of tumor is extremely indistinct.

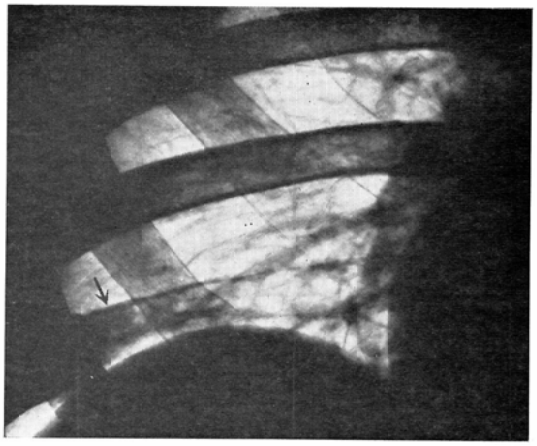

Fig. 7. 35 year old male Eosinophilic granuloma with osteolytic changes diffusely involving the 8 th rib, mixed with dense shadow indicating bone necrosis.

coma, periosteal chondrosarcoma, parosteal fibrosarcoma, and periosteal desmoid are found. In the diagnosis of these parosteal tumors, findings in soft tissue density are important.

2. Findings as regards the shape, contour, and edge

As shown in Fig. 4, most of the benign tumors give cystic, loculated bone defect with density of the tumor comparable to soft tissue with marginal sclerosis and sharp demarcation. In malignant tumors,

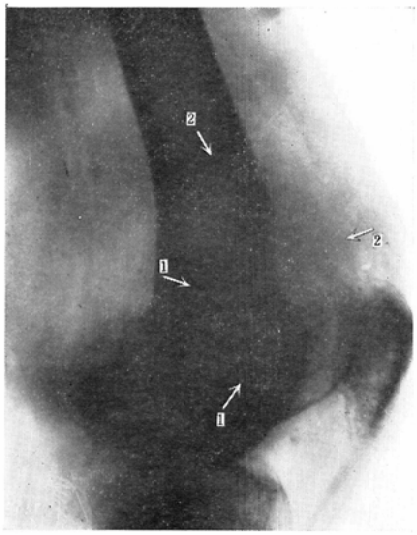

Fig. 8. 23 year old male Malignant giant cell tumor; 1: osteolytic margin, 2: cortical destruction and mass shadow in soft tissue.

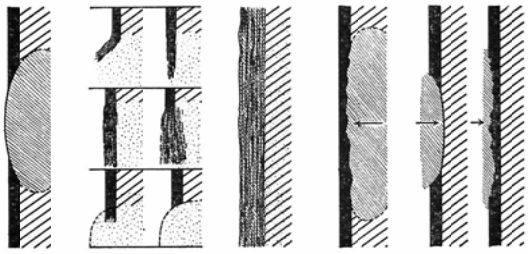

a	b	c	d	e
Benign tumors Malignant tumors (early stage)	Osteogenic sarcoma Chondrosarcoma Fibrosarcoma Reticulum cell sarcoma Liposarcoma Myxosarcoma Metastatic bone tumors Neurosarcoma Xanthoma Chordoma	Ewing's sarcoma Leukemia Osteogenic sarcoma Metastatic bone tumors	Plasmocytoma Xanthoma Leukemia Metastatic bone tumors	Fibrosarcoma Paro-, Periosteal osteogenic sarcoma Parosteal tumors

Fig. 9. Cortical destruction

Fig. 10. 13 year old male Osteogenic sarcoma, shows destruction of cortex as shown in Fig. 9, b.

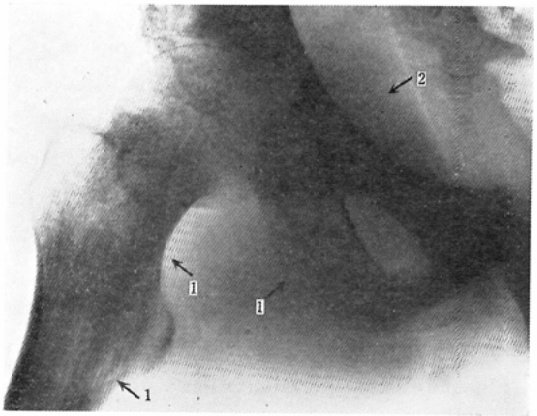

Fig. 11. 15 year old male Ewing's sarcoma, 1: Destruction of cortex as shown in Fig. 9, c. 2: Infiltration of soft tissues.

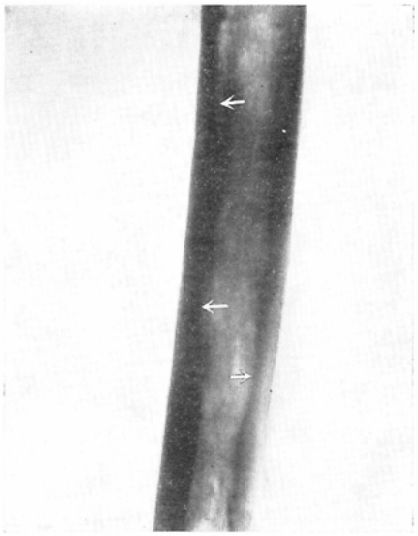

Fig. 12. 65 year old male Plasmocytoma; shows destruction of cortex as shown in Fig. 9, d.

on the other hand, the borderline between the tumor and normal bone is indistinct and the central part usually appears osteolytic, with or without irregular marginal sclerosis. The necrotic tissue and sequestra within the tumor give the appearance of dense flocculation (Fig. 5).

Fig. 6. Osteogenic sarcoma of 36 year old female, with mixed osteosclerotic and osteolytic lesion, and extremely indistinct borders.

Fig. 7. Eosinophilic granuloma of 35 year old male, with osteolytic changes diffusely involving

the 8th rib, mixed with dense shadow indicating bone necrosis.

Fig. 8. Malignant giant cell tumor of 23 year old male, characterized by defective destruction of bone cortex with extensive osteolytic lesion.

3. Picture of destruction of bone cortex.

Fig. 9a, b, c, d and e is the schematic representation of the destruction of bone cortex. The names of the tumors under the Figure represent the tumors frequently giving rise to such findings. a is seen in benign tumor. The bone cortex becomes paper thin due to the compression from inside and erosion, with subsequent bulging towards outside. b is seen in malignant tumor, characterized by irregular destruction of the bone cortex alone, with clear cut defect occasionally. c is caused by proliferation of tumor tissue within the Haversian canal and separation of bone cortex towards the longitudinal direction. d is caused by the compression of the bone cortex from inside by an extensive tumor occurring within the bone marrow. Erosion subsequently occurred. e is seen in malignant and benign parosteal and periosteal tumor. Findings of destruction was intense in malignant cases.

Fig. 10. 13 year old male with osteogenic sarcoma.

Fig. 11. 15 year old male with Ewing's sarcoma.

Fig. 12. 65 year old male with plasmocytoma.

In these 3 cases, destruction of bone cortex occurred as shown in Fig. 9, b, c, and d respectively.

4. Periosteal reaction.

Periosteal reaction is seen in various diseases of the bone, and not specific for bone tumors.

Fig. 13 shows various findings of the periosteum in schematic diagram. Fig. 14 was taken from 1 year old male with leukemia, exhibiting an extensive periosteal reaction accompanied by intense de-

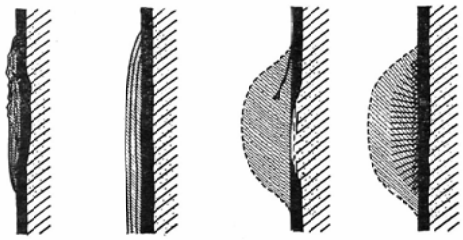

a : Thickening	b : Onion-peel	c : Codman	d : Sun-ray Spicula
Fibrosarcoma	Ewing's sarcoma	Osteogenic sarcoma	Osteogenic sarcoma
Osteogenic sarcoma	Osteogenic sarcoma	Ewing's sarcoma	Ewing's sarcoma
Chondrosarcoma (early stage)	Reticulum cell sarcoma	Hemangioma (subperiosteal bleeding)	Hemangioma (capillary)
Ewing's sarcoma	Chronic Osteomyelitis	Metastatic bone tumor	Ossifying fibroma
Leukemia	Syphilis	Syphilis	Chondrosarcoma (much smaller)
Reticulum cell sarcoma		Tuberculosis	
Hemangioma			
Adamantinoma			

Fig. 13. Periosteal reaction

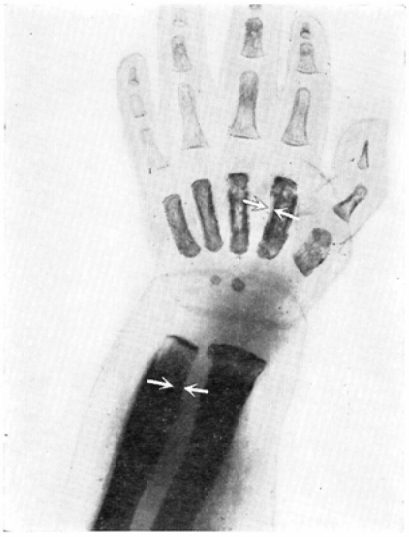

Fig. 14. 1 year old male Leukemia; extensive periosteal reaction accompanied by destruction of the bone cortex.

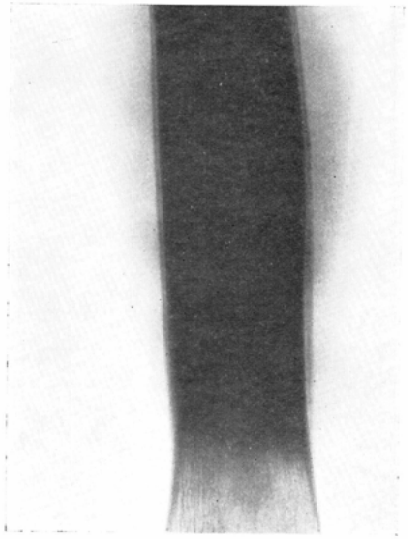

Fig. 15. 13 year old female Osteogenic sarcoma with onion peel picture.

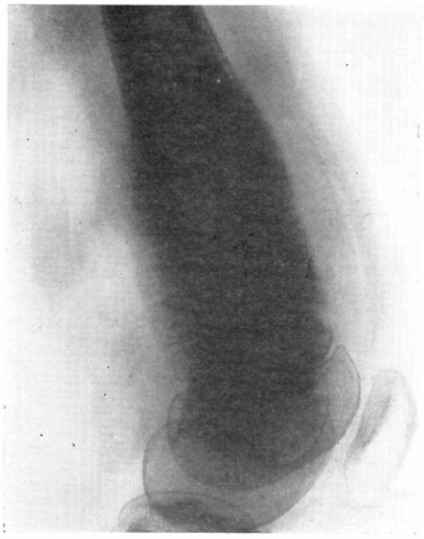

Fig. 16. 15 year old male Osteogenic sarcoma with Sun-ray spicula.

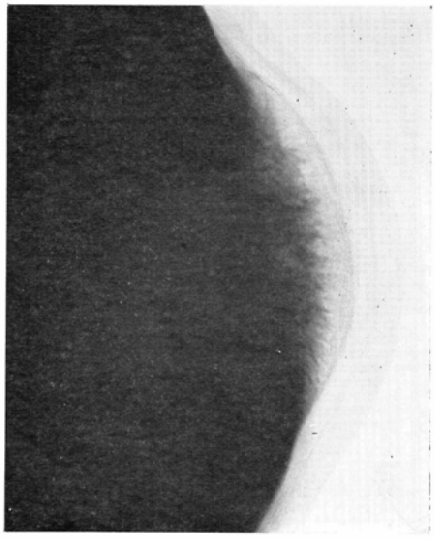

Fig. 17. 28 year old male Capillary hemangioma with Sun-ray spicula.

struction of the bone cortex. After destroying the periosteum, the tumor infiltrated to soft tissue.

Fig. 15. 13 year old female with osteogenic sarcoma with onion peel picture. Such finding is frequently seen in Ewing's sarcoma, and also in osteomyelitis and syphilis.

Fig. 16. 15 year old male with osteogenic sarcoma. Sun-ray spicula, along with Codman's triangle is frequently seen in osteogenic sarcoma and also in capillary hemangioma (Fig. 17. 28 year old male)

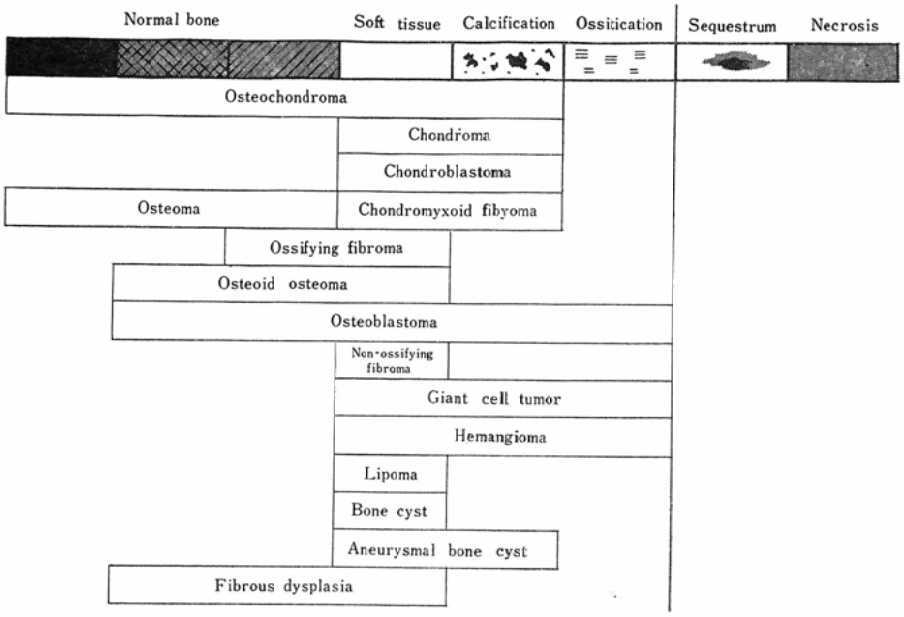

Fig. 18, a. Density of tumor (benign).

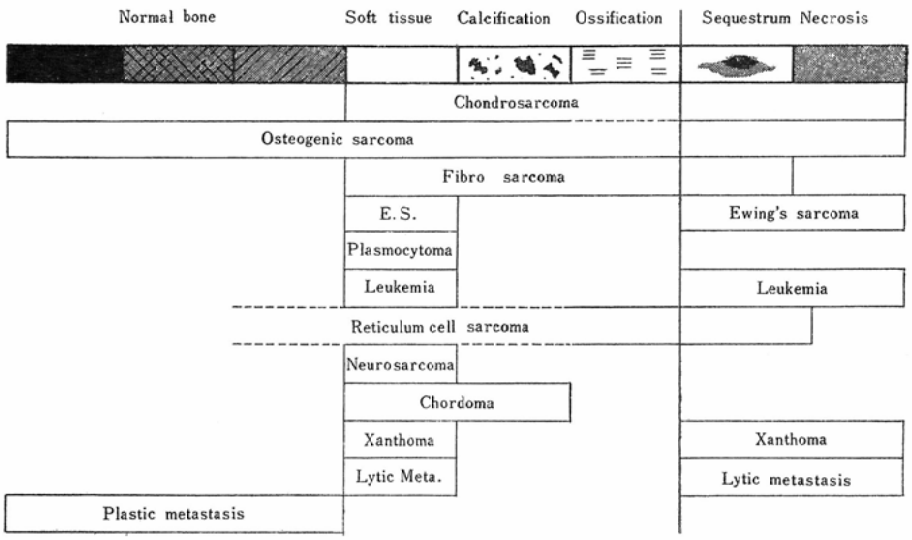

Fig. 18, b. Density of tumor (malignant).

and ossifying fibroma. The latter two give regular picture with minimal bone destruction.

5. Soft tissue density.

Among soft tissue tumors originating from bone tumor, benign tumors such as ecchondroma, hemangioma, aneurysmal bone cyst, and eosinophilic granuloma are found. Giant cell tumor, chordoma,

adamantinoma and neurofibroma are found among the semimalignant varieties. Chondrosarcoma, osteogenic sarcoma, fibrosarcoma, Ewing's sarcoma, leukemia, reticulum cell sarcoma, and myxosarcoma are among the malignant varieties.

The density of most of the tumors of soft tissue is identical with that of normal soft tissue, but various densities originating from bone tissue are included in it. Findings due to circulatory disturbance, inflammation, and edema are added to it. Generally speaking, complex soft tissue density indicates malignancy, as seen in Ewing's sarcoma, osteogenic sarcoma, chondrosarcoma, leukemia, and reticulum cell sarcoma

6. Bone atrophy.

Presence of osteoporosis in the normal portion of the bone in which the tumor is present and in the surrounding bone as a rule indicates malignancy. Localized osteoporosis is found in chondrosarcoma, fibrosarcoma, and xanthoma. Generalized osteoporosis is found in Ewing's sarcoma, plasmocytoma, leukemia, reticulum cell sarcoma and osteogenic sarcoma.

9. Density of bone tumor.

Fig. 18a, b summarized the density in benign and malignant bone tumor. In most of the bone tumor, so-called soft tissue density is seen and the density changed along with the course. In metastasis, the density added to the osteolytic and osteoblastic foundation is relatively mild. In benign tumor, as shown in Fig. 18a, osteosclerotic, osteoblastic, and calcifying tendencies are noted along with the course, resulting in a shift to the left. Findings of sequestrum and necrosis are rather rare. In malignant tumors, on the other hand, as shown in Fig. 18b, findings of sequestrum and necrosis were frequently found, with a tendency toward a shift to the right.

Conclusion

Roentgenological evaluation of the degree of malignancy was made in 165 cases of primary bone tumors of the authors' own experience.

References

1) Chalmes, J., et al.: A metastasising chordoma, J. Bone Joint Surg., 42-B: 556, 1960.
2) Cohen, J.: Simple bone cysts. Studies of cyst fluid in six cases with a theory of pathogenesis, J. Bone Joint Surg., 42-A: 609, 1960.
3) Donaldson, W.F.: Aneurysmal bone cyst, J. Bone Joint Surg., 44-A: 25, 1962.
4) Dowling, E.A.: Mesenchymal chondrosarcoma, J. Bone Joint Surg., 46-A: 747, 1964.
5) Elliott, G.B.: Malignant angioblastoma of long bone, J. Bone Joint Surg., 44-B: 25, 1962.
6) Harris, W.H., Dudley, H.R., Barry, R.J.: The natural history of fibrous dysplasia, J. Bone Joint Surg., 44-A: 207, 1962.
7) Lichtenstein, L., Sawyer, W.R.: Benign osteoblastoma, further observations and report of twenty additional cases, J. Bone Joint Surg., 46-A: 755, 1964.
8) Mackenzie, D.H.: Intraosseous glomus tumours; report of two cases, J. Bone Joint Surg., 44-B: 648, 1962.
9) Middlemiss, J.H.: Cartilage tumours, Brit. J. Radiol., 37: 277, 1964.
10) Ralph, L.L.: Chondromyxoid fibroma of bone, J. Bone Joint Surg., 44-A: 635, 1962.
11) Sherman, R.S. and Wilner, D.: The Roentgen diagnosis of hemangioma of bone, Amer. J. Roentgenol, 86: 1146, 1961.
12) Smith, D.A., et al.: Benign chondroblastoma of bone; report of an unusual case, J. Bone Joint Surg., 44-A: 571, 1962.
13) Tuboku-Metzger, A.F.: Plasmocytoma with unusual radiological findings in the bones, Brit. J. Radiol., 34: 529, 1961.

14) Weinfeld, M.S. and Dudley, H.R.: Osteogenic sarcoma; a follow-up study of the ninety-four cases observed at the Massachusetts General Hospital from 1920 to 1960, J. Bone Joint Surg., 44-A: 269, 1962.