Osaka University Knowledge Archive

Title	Efects of the radiological therapy combined with anticancer drugs
Author(s)	高橋, 直彦
Citation	日本医学放射線学会雑誌. 1967, 27(4), p. 406-420
Version Type	VoR
URL	https://hdl.handle.net/11094/20224
rights	
Note	

Osaka University Knowledge Archive : OUKA

https://ir.library.osaka-u.ac.jp/

Osaka University

特別掲載

EFFECTS OF THE RADIOLOGICAL THERAPY COMBINED WITH ANTICANCER DRUGS

by

Naohiko Takahashi

Department of Radiology, Kobe University, School of Medicine, Kobe, Japan

(Director: Prof. Kazuyuki Narabayashi)

悪性腫瘍に対する放射線・制癌剤併用療法

神戸大学医学部放射線医学教室（指導　楢林和之教授）

高　橋　直　彦

（昭和42年5月15日受付）

放射線と Mitomycin C (MTC), Hg-Hematoporphyrin (MH), Toyomycin (TM) 等制癌剤の併用効果を報告する.

放射線とMTC，MHの併用はこれ等制癌剤単独使用に比しより大きな皮下固型吉田肉腫縮小の効果を示す事を実験的に明らかにした.

各種悪性腫瘍に対する放射線・MTC併用症例は 175例，放射線・MH併用は99例，放射線・TM併用は22例，放射線と上記以外の制癌剤併用は151例ある.

放射線・MTC併用に関しては癌より肉腫に，原発病巣より転移巣に有効であつた．放射線とMTCの夫々単独効果を個々に観察する事ができた68例を検討すると放射線が有効でMTC無効症例は11例あつたが，放射線が無効でMTC有効例は全くない．照射前MTC投与例9例，照射後MTC投与例38例，両者を同時併用例60例につき有効率をみると同時併用が最も高い．この事実は肺癌及び悪性淋巴腫を抽出しても同様であつた.

多発性悪性淋巴腫7例につき，MTCを全身投与しつつ一病巣にのみ放射線治療を行い，両者の縮小率をしらべた結果，両者併用の有効性を認める事ができた.

肺癌 128例に放射線・MTC併用療法を行い，腫瘍影縮小率及び生存率を検討したが，放射線単独の場合と著差を見出し得なかつた.

放射線・MTC併用は放射線単独に比し造血臓器に対する障害発年率は高く，又その程度も高度になる傾向があるが完全照射を阻げる程のものではなかつた.

放射線・MH併用症例では夫々の単独の場合以上の効果の増強はみとめられなかつた.

即ち，悪性淋巴腫の如き肉腫系のものでは両者の併用効果を実験的，臨床的に確認し得たが癌ではその効果を明確に把握出来なかつた．しかし併用に関して特に治療続行困難になる程の副作用はないことが判つた.

Introduction

Radiation therapy for malignant tumor has made a great progress in recent years. In our clinic, we have also performed radiation therapy using x-rays, radium, γ-rays of Co-60 and electron beam by 18 MeV betatron with good results.

Many studies have been made to enhance the radiation effect using chemical agents such as anticancer drug and radiosensitizer[1)12)15)21)22)]. Some reports have proved the enhanced radiation response by adequate administration of chemotherapeutic agents, while other reports have denied effectiveness of these technique. According to these papers, the materials, combination program and criterion of treatment efficacy seemed to have differed greatly in these reports. The study should require clinical cases to be selected at random from the same group of neoplastic diseases to be compared with the other method, and it has been found even histologically similar malignant neoplasma often show diverse response to irradiation and combined therapy.

It is hardly possible clinically, therefore, to obtain strictly identical materials in this sense.

The purpose of this investigation was to determine whether combined therapy would improve the radiation effect, and to find the effective regimen for such joint therapy.

The chemotherapeutic agents used in this study were: namely, Mitomycin C (MTC), Hg-hematoporphyrin (MH) and Toyomycin (TM), the products of Japan.

The expected effects of combined therapy on the malignant tumor are:

1. The combined therapy causes greater destruction of the cancer tissue and affords more intense regression of the tumor than those in the single method. The parameter of this effects may be the rate of regression[5)7)8)15)18)].

2. The anticancer drugs exert systemic effect and expected to work on the main lesion and also on the undetected metastases, while radiation offers limited local effect. The parameter of this effects may be the prolongation of survival time[4)20)23)].

Survival time and objective regression of tumor must be used as a parameter of combined effect and to avoid inaccuracy of using subjective symptomatic improvement as the measurement[17)].

One of the problems awaiting solution is the determination of the most effective method of combination therapy—Simultaneous administration, and chemotherapy before and after radiation therapy.

To confirm the combined clinical effect, the laboratory studies must be carried out[3)23)27)].

Anticancer Drugs Employed

Following three chemotherapuetic drugs were used for the combination therapy in this study.

Mitomycin C (MTC) was discovered by Dr. T. Hata in 1956[11)24)]. It is the violet crystal which is obtained from streptomyces caespitosus and is composed of the three anticancer groups such as quinone, urethane and ethyleneimine group (Fig. 1).

It has been histologically confirmed that MTC is possessed of power to destroying the cancer cells by means of the degeneration of chromatin within the nucleus; biochemically, it inhibits the cellular fission of the cancer cells by preventing the biosynthesis of desoxyribose nucleic acid.

It seems to be the most available and the representive anticancer drug used in Japan[12)19)26)], because of its strong anticancer action, although MTC often produces the leukopenia and bleeding tendency as a side reaction[18)].

Hg-hematoporphyrin (MH) is a kind of sodium salt of hematoporphyrin mercury which has also been discovered in Japan in 1954, which is powder presenting dark brownish color. The chemical structure is shown in the figure (Fig. 2).

Hg-hematoporphyrin inhibits the growth of tumors of the experimental animal as a results of

Fig. 1. Chemical structure of MTC.

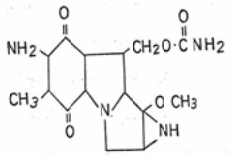

Fig. 2. Chemical structure of MH.

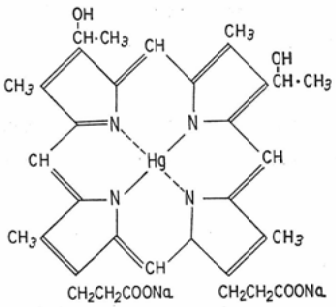

Fig. 3. Scintigram revealed a concentratian of ^{203}Hg-MH in the tumor of the left thigh.

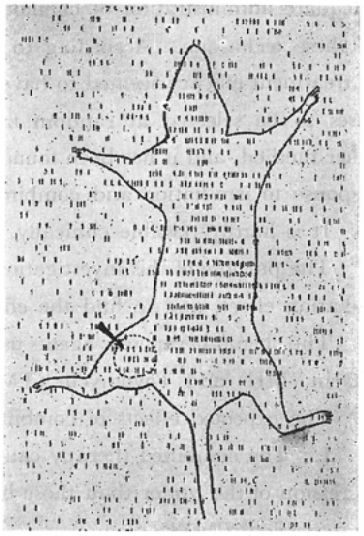

the depressing action to the desoxyribonuclease and ribonuclease especially to desoxyribonuclease. Hg-hematoporphyrin competes the decreasing action of toxohomone to the hepatic catalase[25].

It was though that neoplastic tissue have an affinity for metalloporphyrin[6]. The specific affinity of ^{203}Hg-MH to the experimental tumor has been discovered during this study.

Five rats with subcutaneous experimental Yoshida sarcoma were given 10 μCi of ^{203}Hg-hematoporphyrin intravenously, and they were scanned at 24 hours. The solid tumor in the subcutaneous tissue of the rats which was developed experimentally by transplantation of the ascites cells of the Yoshida sarcoma have given positive spot by scanning in all cases (Fig. 3). On the scintigram, highly accumulated radioactive substance could be detected in the tumor site in the left thigh. The each organ prepared and count per minute per gram of each tissue was counted using the well-type scintillation counter. It has been demonstrated that tumor had received far more radioactive strength than the other tissues. An average ^{203}Hg-hematoporphyrin uptake ratio of each organ obtained from five rats is shown in table (Table 1).

The specific affinity of ^{203}Hg-hematoporphyrin to the experimental tumor has also been ascertained on AH 130 solid ascites hepatoma bearing rats (Table 2).

Table. 1 Distribution of ^{203}Hg-Hematoporphyrin in Yoshida Sarcoma bearing Rat after 24 hrs i.v. (Mean ± S.D. of 5 rats)

Spleen	33.0± 2.8c.p.m
Tumor	25.5± 9.7
Kidney	23.5± 3.4
Liver	16.5±11.7
Muscle	11.0± 4.6

Table. 2 Distribution of ^{203}Hg-Hematoporphyrin in AH 130 Solid Ascites Hepatoma bearing Rat after 24 hrs i.v. (Mean ± S.D. of 5 rats)

Kidney	13.1± 1.3c.p.m
Liver	9.1± 0.4
Spleen	5.1± 0.6
Tumor	5.0± 0.2
Lung	3.0± 0.3
Muscle	0.4± 0.2

Toyomycin (TM) is the chromomycin A_3 which is discovered in 1951 in Japan and extracted from culture media of streptomyces griseus. Toyomycin is supplied as a yellowish crystalloid powder and the chemical formula is not yet determined. Toyomycin produces the cellular destruction of the cancer causing appearance of PAS granules. Biochemically, Toyomycin can slightly decrease the cellular respiration and glycolysis in the cancer tissue and prevents the uptake of P-32 into DNA and RNA[14].

Experimental Study

In order to confirm whether the effect of this combination therapy has been successful or not, the following experiment were attempted.

A model experiment to evaluate the combined effects were carried out on the solid subcutaneous Yoshida sarcoma similar to human malignant neoplasma.

The animals: These animals used in this study were female adult inbred rats of the pure strain Donryu obtained from Nippon Rat Co.. The animals weighing 150 to 200 gm. were placed in cages under air condition. Synthetic diet and drinking water were supplied ad lib.

Tumors: These animals were inoculated subcutaneously in the thigh with Yoshida sarcoma ascitic fluid containing approximately fifty thousand cells. When the transplanted tumor had grown up to the size of 15×15 mm in the nodule diameter on the seventh day after inoculation, they were sacrificed for the observation.

The animals were divided according to the treatment schedule into four groups. The second and third groups consist of fifteen rats each which were divided into three subgroups of five rats each, and other two groups consist of five rats each. The first group received radiation alone. The subgroups of the second group were administered of the anticancer drugs- MTC, MH and TM-alone. The subgroups of the third group were given the combined radiation and anticancer drugs as above. The fourth one served as the control. With the first group, single radiation dosage of 600 roentgens was given. The radiation factors were: 180 KV, 20 mA, 30 cm T.S.D., 0.9 mmCu, 0.5 mmAl Filter. The animals were shielded by adequate lead box prevented from unnecessary exposure. The tumor bearing leg only was exposed in the x-rays. Rats of each subgroups of the second group were given 0.1 mg of MTC, 1.25 mg of MH or 0.025 mg of TM intraperitoneally respectively. An intraperitoneal injection of these chemotherapeutics was given 30 minutes before the x-ray irradiation on the third group.

Serial measurements of tumor diameter were taken daily during the course of the experiment.

The results of treatments have been based on the size of respective tumor by comparing with its size before the treatment. The size of tumor before therapy was expressed as equivalent to one hundred.

Serial change in the tumor size of the four groups are shown in the treatment and reaction chart. Relative tumor volume plotted against time in days. Radiation with MTC group shows the most remarkable regression.

Although the value has increased from 100 to 296 after 4 days in the control group, those of radiation group decreased from 100 to 54, and those MTC group decreased to 37. When MTC was combined with radiation therapy, its values decreased to 21. This method was found to be most effective, and the rate of regression of the group treated by this method shows significant difference to the group treated by radiation alone (Fig. 4).

In the group of MH alone, the value increased to 211, which means that there is slight inhibiting

Fig. 4. Effects of combination therapy of MTC and radiation on the growth of solid Yoshida sarcoma.

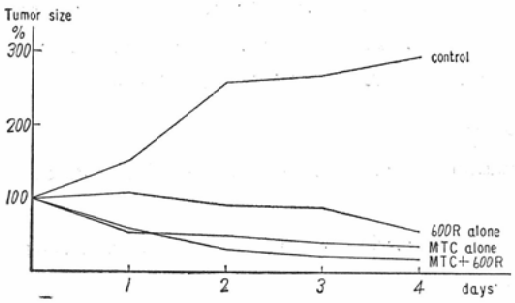

Fig. 5. Effects of combination therapy of MH and radiation on the growth of solid Yoshida sarcoma.

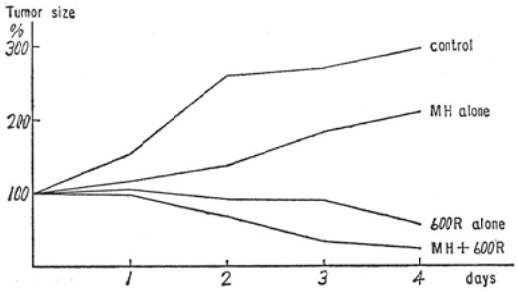

Fig. 6. Effects of combination therapy of TM and radiation on the growth of solid Yoshida sarcoma.

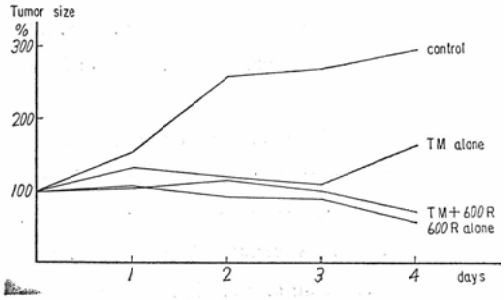

effect to the tumor growth comparing the control. However in the group of combination therapy with radiation its value decreased to 25. This method increased the therapeutic effect (Fig. 5).

However, in the group of TM which was not so effective on the tumor growth as MTC and MH, the value of TM alone increased to 165 showing inhibition of growth compared to control. No augmented effect could be gained on the combination of radiation and TM (Fig. 6).

It can be concluded if the indication of the combination thereapy has been adequately selected, the better results will be obtained in comparison with the single use of MTC, MH or radiation therapy.

Clinical Study

Treatment Plan

The treatment plans for the study of the combinaion therapy were:

Plan I. One full course of chemotherapy was first administered then, followed by the course of radiation therapy, hence, chemotherapeutic management should be completed first.

Plan II. A course of radiation thepray was to be given simultaneously with the course of chemotherapy from the first day of the therapy, that is, two types of treatment were combined. simultaneously.

Plan III. The patient was given a course of radiation therapy, which was supplemented by the course of chemical treatment, that is, the course of chemotherapy to be carried out after complete irradiation.

The other special plan has been adopted on the some cases of the malignant lymphoma.

Treatment Technique

The principal standard technique for this therapy are as follows:

1) The tumor was irradiated mainly with telecobalt unit (source: 2,000 Ci, source tumor distance 30 or 40 cm). The radiation employed in the some cases was electron beam of betatron(18 MeV). Tumor dose of 4,500 to 6,000 R delivered in 3 to 4 weeks.

2) MTC was administered intravenously 2 mg every day, or 4 mg every other day, and from 40 to 60 mg of total dose.

3) MH was given by intravenous injection of 25 mg daily and 500–1,000 mg totally.

4) TM was injected intravenously 0.5 mg daily and 10 mg totally for 20 days.

Evaluation of Effects

The effects of the therapy were evaluated objetively either by direct measurement of palpable nodules or by x-ray findings.

The results of the therapy were classified into three groups.

1) Remarkable imporvement: signifies complete disappearance or marked regression with absorption of the tumors to more than three fourth.

2) Improvement: signifies apparent shrinking of the tumor less than three quarters.

The effective cases include both first and second group.

3) No improvement cases were which demonstrated no effect. The effects of growth inhibition was not included.

The effects were estimated at the end of therapy on completely treated tumor size comparing to the size of the tumor before treatment.

The some other observations made on the cases of malignant lymphoma and pulmonary carcinoma.

Cases Treated with Combination Therapy

Following cases with cancers and sarcomas were treated with combined radiation with the anti-cancer drugs. One hundred and seventy five patients in this series received combined radiation and MTC, 99 patients received combined radiation and MH, while 22 patients received combination of radiation and TM. The other remaining 105 cases were treated with combined radiation and other drugs such as Nitromin, Thio TEPA, Actinomycin D and cyclophosphamide. Forty six patients were administered of combined radiation and two or more of the above mentioned aticancer drugs. Table 3 summarizes the cases treated with the therapy combined.

Combination Therapy of Radiation and MTC

Efficacy of the combined therapy with radiation and MTC is observed in 175 cases, covering various diseases are summarized in table 4.

Of 175 patients, 125 patients with an average age of 53.5 years had cancers,while 50 patients with an average of 40.6 years had sarcomas. The most case were with lung cancer and malignant lymphoma. One hundred and five patients were male and 70 were female with an average age of 51.1 years and 48.3 years.

The percentage of effectiveness with the combination therapy were studied.

Table. 3 Summary of Cases of Combination Therapy of Radiation Therapy and Anticancer Drugs

Anticancer drug	No. of cases
Mitomycin C	175
Hematoporphyrin-Hg	99
Toyomycin	22
Thio TEPA	85
Other miscellaneous	20
Combination of two or more drugs	46
TOTAL	447

Table. 4 Summary of Cases of Combination of Radiation and MTC Therapy

	TOTAL	175
Cancer 125	Lung cancer	42
	Carcinoma of head and neck	25
	Postoperative recurrence of breast cancer	15
	Postoperative recurrence of gastric cancer	12
	Carcinoma of alimentary tract except stomach	6
	Postoperative recurrence of malignant struma	5
	Other miscellaneous cancer	20
Sarcoma 50	Reticulosarcoma	21
	Lymphsarcoma	7
	Hodgkin's disease	6
	Osteogenic sarcoma	5
	Postoperative recurrence of seminoma	4
	Other miscellaneous	7

Table. 5 Effects of Combination Therapy of Radiation and MTC on Various Carcinomas and Sarcomas

	Remarkably improved	Improved	Ineffective
Carcinoma 70 cases	21 (30.0%)	22 (31.4%)	27 (38.6%)
Sarcoma 37 cases	15 (40.5%)	17 (46.0%)	5 (13.5%)

Table. 6 Effects of Combination Therapy of Radiation and MTC

TOTAL	68 cases
Both therapy effective	32 (47.1%)
Radiation effective, MTC ineffective	11 (16.2%)
Radiation ineffective, MTC effective	0 (0%)
Neither therapy effective	25 (36.8%)

Twenty one cases (30.0%) out of 70 cases of various carcinomas and 15 (40.5%) out of 37 cases of various sarcomas showed remarkable improvement. And 22 (31.4%) cases with carcinomas and 17 (46.0%) cases with sarcomas showed improvement. As a summary, 75 (70.1%) cases with various malignant neoplasma showed effective response to the combination therapy (Table 5).

Following study was made to judge whether radiation or MTC are actually working in the regression of tumor. The cases with two or more tumors were selected. The individual effects of the both therapy were able to be judged on the lesion in which the both therapy were not given jointly.

Thirty two (47.1%) out of 68 cases responded both to radiation and to MTC therapy. Eleven (16.2%) cases showed effective response to radiation therapy, but with MTC no effect could be seen. Out of cases unresponsive to the radiation therapy, none showed sings of reaction to the MTC therapy. Twenty five (36.8%) cases have failed to show the therapeutic effect (Table 6).

From these results, it can be stated that the cases showing good response to the MTC therapy are also proved to be effective to the radiation therapy, while, some cases less reactive to MTC showed some response to radiation therapy.

Therefore, MTC should not be given to the cases in which radiation therapy is found to be least effective.

Three out of 9 cases (33.3%) of the plan I group, 48 out of 60 cases (80.0%) of the plan II group and 24 out of 38 cases (63.2%) of the plan III group showed improvement. The second group, i.e. the simultaneous combination therapy seems to be the most effective method in the three treatment plans.

Table. 7 Effects of combination therapy of radiation and MTC

		Remarkably improved	Improved	Ineffective
Carcinoma	Plan I	1	1	5 (71%)
	Plan II	7	17	10 (29%)
	Plan III	13	4	12 (41%)
Sarcoma	Plan I	0	1	1 (50%)
	Plan II	12	12	2 (8%)
	Plan III	3	4	2 (22%)

Table. 8 Effects of combination therapy on carcinoma and sarcoma

		Effective	Ineffective
Carcinoma	70 cases	43 (61.4%)	27 (38.6%)
Sarcoma	37 cases	32 (86.5%)	5 (13.5%)

In the case of cancer, 2 out of 7 cases (28.6%) of the plan I, 24 out of 34 cases (70.6%) of the plan II and 17 out of 29 cases (58.6%) of the plan III group showed improvement. In the case of sarcoma, 1 out of 2 cases (50.0%) of the plan I, 24 out of 26 cases (92.3%) of the plan II and 7 out of 9 cases (77.8%)of the plan III group showed improvement. In the both groups of cancer and sarcoma, the plan II has proved to be the most reliable method (Table 7).

Forty three cases (61.4%) out of 70 cases with carcinomas and 32 (86.5%) out of 37 cases with sarcomas were amenable to the combination therapy. It is observed that this regimen has shown stronger influence against the sarcomas than the carcinomas (Table 8).

The effectivity of the combined therapy on the malignant lymphoma and the pulmonary carcinoma were observed. The radiation therapy as well as MTC therapy seemed to be quite effective for the malignant lymphomas, however, the lung cancer showed least reactivity to the both treatments.

In the cases of the malignant lymphoma, 1 out of 2 cases (50%) of the plan I, 14 out of 16 cases (87.5%) of the plan II and 4 out of 6 cases (66.7%) of the plan III group showed improvement. In the cases of lung cancer, none out of 4 cases (0%) of the plan I, 13 out of 18 cases (72.2%) of the plan II, 2 out of 8 cases (25%) of the plan III group showed improvement. Thus, the excellence of plan II therapy in the treatment of malignant lymphoma and lung cancer have been reasonably demonstrated (Table 9).

Table. 9 Effects of combination therapy of radiation and MTC on the malignant lymphoma and the pulmonary carcinoma

		Remarkably improved	Improved	Ineffective
Malignant lymphoma	Plan I	0	1	1 (50%)
	Plan II	7	7	2 (12%)
	Plan III	2	2	2 (33%)
Pulmonary Carcinoma	Plan I	0	0	4(100%)
	Plan II	4	9	5 (28%)
	Plan III	2	0	6 (75%)

Table. 10 Effects of combination therapy on primary and metastatic lesions

		Effective	Ineffective
Carcinoma	Primary	23 (54%)	20
	Metastatic	20 (74%)	7
Sarcoma	Primary	17 (77%)	5
	Metastatic	15(100%)	0

In the case of primary lesions, 23 out of 43 cases (53.5%) of carcinoma and 17 out of 22 cases (77.3%) of sarcoma reacted to the combined method. In the case of metastatic lesions, 20 out of 27 cases (74.1%) of carcinoma and all cases of sarcoma have exhibited the signs of effect. The metastatic lesions are appear to be more susceptible to the combined management than the primary tumors (Table 10).

Observations on Lung Cancer

Comparative studies on the resutls of combination therapy and those obtained previously by radiation exclusively have been made in a non-random series of patients with pulmonary carcinoma.

Some clinical data of these two groups are described in Table 11, suggesting that the two groups have shown the relative clinical similarity.

Table. 11 Cases of Pulmonary Carcinoma

Clinical data		Treatment plan	
		Combination	Radiation alone
Sex	Male	29	230
	Female	10	61
Age	Average	59.9	58.9
	Range	38—77	25—79
Stage	I	0	1
	II	0	22
	III	13	52
	IV	26	180

Table. 12 Histology of Pulmonary Carcinoma

Type of carc.	No. of cases	
	Combin-ation	Radiation alone
Squamous cell carc.	2	49
Undifferentiated carc.	4	65
Adenocarc.	1	56
Alveolar cell carc.	0	3

The diagnosis of pulmonary carcinoma was established by x-ray findings, scalene or supraclavicular lymphnode biopsy, cytology of expectorated sputum, bronchial abrasion, bronchoscopy, bronchogram and angiogram of bronchial arteries.

The histology of tumors were summarized in Table 12.

Table 13 demonstrates the objective response to the radiation therapy with and without MTC therapy. There are no significant differences in the percent regression of lung cancer in both therapy.

Table. 13 Regression of tumor shadow in lung cancer

	Improved cases	Total cases
Telecobalt alone	77 (75.5%)	102
Combination of telecobalt and MTC	19 (73.1%)	26

Table. 14 Survival rate of pulmonary carcinoma

	Combination therapy	Radiation alone
I st stage	(0 case)	(0 case)
II nd stage	(0 case)	24.5± 5.4 months (13 cases)
III rd stage	17.5± 7.1 months (10 cases)	17.1± 2.0 months (44 cases)
IV th stage	5.1± 3.7 months (20 cases)	6.2± 0.5 months (140 cases)

Mean survival time, mean ± S.E.

An analysis of the long term results were judged by the mean survival time after the first day of the course of the therapy.

The mean survival of 17.5 months with a standard error of ±7.1 months after combination of radiation and MTC were obtained in 10 cases of third stage. The longest survival in this group was 6 months, and the shortest was 3 months.

Mean survival with S.E. was 17.1±2.0 in the 44 cases of third stage treated by radiation alone. The longest in this group was 16 years and 4 months, and the shortest was only a few days.

Mean survival with S.E. of fourth stage was 5.1±3.7 and 6.2±0.5 months in the 20 cases treated by

combination therapy and in the 140 cases treated by radiation alone.

Mean survival with S.E. was 24.5±5.4 in the 13 cases of second stage treated by radiation alone (Table 14).

There is no significant increase in the survival time of patients with lung cancer of third and fourth stage after combination therapy of radiation and MTC.

Observations on Malignant Lymphoma

In the trial of intravenous administration of MTC in the patients with malignant lymphoma developed of multiple metastatic involvement of the lymphnodes, one group of lymphnodes metastasis has received the simultaneous radiation therapy.

The following case reports demonstrate the application of this therapeutic method.

Case 1. K.M. Sixty-eight years old woman, was admitted in December, 2, 1960, with bilateral lymphadenopathy of the cervical, axillar and inguinal lymphnodes. The excision of the inguinal lymphnode revealed a pathologic diagnosis of reticulosarcoma. MTC were administered intravenously at daily dose of 2 mg throughout the course of the therapy combined with joint telecobalt irradiation to the right axillar tumors. This right axillar tumors were treated by combination of radiation and MTC, which eventually disappeared after 3,600 R of tumor dose had been irradiated. The left axillar and inguinal tumors treated with MTC alone had remained showing reduction of its size to approximately three fourth of the original size. Following additional irradiation to the remaining tumors in the left axilla, the tumors had disappeared.

Case 2. A 31 year old man was admitted in October, 10, 1964. He had underwent a surgery for Hodgkin's disease in 1961, but complaining with insidious growth of multiple subcutaneous tumors. Biopsy of one node revealed a metastatic recurrence of Hodgkin's disease. Four milligrams of MTC was intravenously administered every other day. The right anterior chest tumor received cobalt-60 γ-ray treatment, for other tumors MTC alone were given, and the left flank tumor was measured as a control. Daily measurement of the tumors were taken. With the therapy, tumor mass began to show regression from 43.4 cm^2 to 17.7 cm^2 (40.8%) in its size which was no more difference than the control tumor (from 30.4 cm^2 to 14.4 cm^2, 47.4%).

Case 3. A 66 year old man was hospitalized in June, 6, 1964, with reticulosarcoma disseminated throughout the body. The biopsy of one node proved its histology. Two milligrams of MTC were administered daily intravenously. From the outset of the MTC therapy, telecurie therapy to the left anterior chest wall was tried, resulting in marked shrinking and absorption from 12 cm^2 to 4.7 cm^2 (39.2 %). The one of other tumor not receiving telecurie therapy, for example, tumor of the left thigh become smaller in its size from 3.1 cm^2 to 2.5 cm^2 (80.6%), apparently demonstrating superiority over a therapy confined to MTC in the tumor regressing effects, thus the combined effect was well proved.

As shown in these cases, 7 cases with multiple foci of the malignnt lymphoma were irradiated locally to one lesion, and MTC were administered throughout the course of radiation therapy. The effects of the combination therapy could be estimated on one irradiated lesion, while, the effects of MTC were observed on the other lesions. The following results were obtained as shown in Table 15. In the lesions treated with combined radiation and MTC, 6 out of 7 lesions (85.7%) showed remarkable improvement, and the other one showed improvement. In the lesions treated with MTC alone, none showed remarkable im-

Table. 15 Effects of combination therapy of radiation and MTC on the malignant lymphoma

	Remarkably improved	Improved	Ineffective
Simultaneous combination of rad. & MTC	6 lesions	1 lesion	0
MTC alone	0	4	3
Radiation after MTC	3	4	0

provement, 4 out of 7 lesions (57.1%) showed improvement. By means of additional telecobalt therapy to remaining tumors, 3 out of 7 lesions (42.9%) showed remarkable improvement, and the other lesions (57.1%) showed improvement.

It was concluded that the combination therapy had been more effective than the single therapy of MTC or radiation therapy, so that the joint therapy appears to be worth trying in the clinical management of the malignant lymphoma.

Side Effects

The side effects of combined therapy of radiation with MTC on the blood counts were found more often than the side effects of the each therapy. The chief toxic reaction of MTC is damage to the hematopoietic organs. The leukopenic and anemic reactions of the radiation were added to this untoward effects. The augumented side reactions on combination therapy have been frequently encountered in the poorly nourished and weak patients. The cases which are sensitive to the radiation with reduced leucocyte count are equally sensitive to MTC therapy. The leukopenia was observed more frequently in the combined therapy than in the radiation therapy alone. The thrombocytopenia and bleeding tendency also appeared two to three times more frequently than in the straight radiation therapy (Table 16).

Table. 16 Side Effects on Blood Count

	Combination therapy	Radiation alone
Anemia	8/67 cases (11.9%)	2/34 cases (5.9%)
Leukopenia	36/67 (53.7%)	15/34 (44.1%)
Thrombocytopenia	23/67 (34.3%)	5/34 (14.7%)
Bleeding tendency	5/67 (7.5%)	2/34 (5.9%)

Table. 18 Side Effects of Combination Therapy on Liver Function

B.S.P. test	> 7.5%/30min.	1/54	1.8%
Serum Cobalt test	~R 3.4~	3/30	10.0%
Serum protein	< 6.1 g/dl	2/63	3.2%
Urine urobilinogen	increased	9/71	12.7%

Table. 17 Side Effects of Combination Therapy on Leucocyte and Thrombocyte Count

		Combination therapy	Radiation alone
Leucocyte	~ 7,000	10 cases	7 cases
	6,000~	1	7
	5,000~	2	1
	4,000~	2	3
	3,000~	3	0
	2,000~	1	1
	1,000~	0	0
	TOTAL	19	19
Thrombocyte	~ 110,000	7	12
	110,000~	3	3
	90,000~	3	2
	70,000~	3	2
	50,000~	2	0
	30,000~	1	0
	TOTAL	19	19

More severe leukopenia and thrombocytopenia have been observed in the combined therapy than in exclusive radiation therapy (Table 17). One of the lung cancers had an attack of panhematopenia following such therapy, and died from subcutaneous, bronchial and intestinal bleedings. All other cases were able to tolerate the full course of the joint therapy despite the occurrence of undesirable side reactions under adequate treatment.

Liver function test were carried out on the day of admission and the day one week after the termination of the course of the combination therapy (Table 18). The liver function test remained unchanged and no significant liver impairment was observed.

Combination Therapy of Radiation and MH

Ninety nine patients have received radiation treatment with MH.

The combined therapy of radiation and MH was given to the patients in poor condition who were suffering from advanced malignant neoplasms of inoperable type and because of its less side reaction. It is believed that MH have less destructive power against the tumor than MTC, and exerts lesser side effects to the hematopoietic system. The patient who were weak received combined MH and radiation, and those who presented better condition were put on radiation and MTC.

Ninety nine cases were treated with radiation and MH jointly (Table 19). The primary lung cancer constituted the major cases, while the second were postoperative recurrence of gastric cancer.

Table. 19 Cases treated with combination therapy of radiation and MH

	TOTAL	99
Carcinoma 87	Pulmonary carcinoma	23
	Carcinoma of head and neck	18
	Postoperative recurrence of gastric carcinoma	15
	Oesophageal carcinoma	5
	Postoperative recurrence of breast carcinoma	5
	Carcinoma of colon	8
	Malignant struma	5
	Carcinoma of rectum	3
	Miscellaneous	5
Sarcoma 12	Lymphsarcoma	3
	Postoperative recurrence of seminoma	3
	Reticulosarcoma	2
	Miscellaneous	4

Table. 20 Effects of combination therapy of radiation and MH

	Effective	Ineffective
Plan I	2 (50%)	2 (50%)
Plan II	16 (64%)	9 (36%)
Plan III	2 (20%)	8 (80%)

The effects of combination therapy of radiation and MH were observed in 39 cases. Two out of 4 cases (50%) of plan I group, 16 out of 25 cases (64%) of the plan II group and 2 out of 10 cases (20%) of plan III group showed improvement. There is no relationship between the treatment plan and its effects, as in combination therapy of radiation and MTC (Table 20).

Combination Therapy of Radiation and TM

There was no difference in the response between the patients who received combined radiation and TM and those who received radiation alone. No increased rate of regression was observed with the radiation and TM treatment. These results were in just accord with the results of experimental animal tumor.

Limit of the Combination Therapy

The method and the route of administration of respective treatment could be adapted freely in combination therapy. But combined method offers somewhat narrow sphere of activity, because therapy requires strict simultaneous treatment schedule.

Skin reaction in combined therapy were the same as in the straight radiation treatment. Although severe damage of the hematopoietic organs might occur in such regimen but the adequate measures such as whole blood transfusion would be possible to forestall the disturbance. Unavoidable therapeutic effect might influence with terminal aggravation of the general condition.

While, the therapy is essentially a palliative, and not of radical measure, and from the rate of regression and prolongation of survival times, the combination therapy should not be a dependable dramatic remedy.

Discussion

Certain therapeutic benefits obtained through the combination therapy of radiation and chemotherapy have been reported. Various workers reported the cmobined effect on the experimental tumor [3,23,27]. Others pointed out the usefulness of such method on the basis of clinical experience. There are few studies on the subject both on the experimentl and clinical aspects. It is important that for the treatment of malignancies, combined method of therapy should be tried. There are considerable differences in the effects between experimental and clinical results. The effects of combination therapy observed in the clinical study has not been so remarkable as in experimental studies. It has been shown that combined effect of radiation and MTC seemed to exert on the regression of solid Yoshida sarcoma, which may be due to the synergistic action. The same regressive effect could not be obtained however, when combination of radiation with TM.

If following factors have been met clinically, the combined therapy woud be most effective. It has been demonstrated that:

1) Greater rate and larger percentage of regression obtained than the radiation alone.
2) Longer survival time would be longer than radiation alone.
3) Size of sample enough for statistic test.
4) Marked differences of the terapeutic effects statistically.
5) Therapeutic technique is less complicated.
6) Broadness of its anticancer spectrum.
7) Less serious side effect.

For effectiveness of cancer therapy the above are the criteria to be adhered to prove clinical value.

It has been clearly demonstrated that radiation therapy and MTC therapy must be administered simultaneously in combination therapy. The MTC therapy should be administered to the case, those responsive to the radiation therapy. It seemed possible that combined radiation and MTC might cause more severe damage to malignant lymphoma than the MTC therapy[2,13,17]. It may be that combination of radiation and MTC do not produce the prolongation of survival time and elevation on rate of regression of lung cancer. It may possible that both oxygen and MTC in combination with radiation therapy might have a marked effect on cancer without increased systemic reactions.

Summary

1) Studies on the effects of the combination therapy of radiation and the anticancer drugs (Mitomycin

C. Hg-Hematoporphyrin and Toyomycin) were reported.

2) There was a remarkable improvement in the regression of solid subcutaneous Yoshida sarcoma receiving the combined therapy of radiation and a anticancer drugs (MTC, MH).

3) One hundred and seventy five patients with several carcinomas and sarcomas were treated with combined radiation and MTC in order to observe the enhanced effects of such combination. Ninety nine patients were treated with combined radiation and MH. One hundred and seventy three patients were treated jointly with radiation and other drugs.

4) In 107 cases, simultaneous combination of radiation and MTC are more effective than the effects in separate administration.

5) In 7 cases with malignant lymphoma, the effects of combined therapy of radiation and MTC seemed to be greater than the straight MTC therapy.

6) In 128 cases with lung cancer, combined therapy exerted similar effect as the straight radiation therapy.

This study failed to demonstrate a prolongation of survival time in patients with lung cancer with an addition of MTC to radiation therapy.

7) More severe damage on the hematopoietic organs were observed in the combined therapy of radiation and MTC than the exclusive radiation method, however, side effects do not interfere the administration of full therapeutic dosage.

8) Augumented effects by means of combined radiation and MH were not observed clinically.

Acknowledgment

Grateful acknowledgements are due to Professor Kazuyuki Narabayashi for his constant interest and guidance in this investigation. I also wish to express my thanks to the staff of Department of Radiology, School of Medicine, Kobe University for their assistance. Particular thanks are due to Drs. S. Kimura, T. Ishida and K. Kondo.

References

1) Bane, H.N., Conrad, J.T. and Tarnowski, G.S.: Combination therapy of malignant tumors with ionizing radiations and chemicals. Cancer Res., 17:551–566, 1957.
2) Cook, J.C., Krabbenhoft, K.L. and Leucutia, T.: Combined radiation and nitrogen mustard therapy in Hodgkin's disease as compared with radiation therapy alone. Amer. J. Roentgenol., 82:651–657, 1959.
3) D'Angio, G.J., Farber, S. and Maddock, C.L.: Potentiation of x-ray effects by Actinomycin D. Radiology, 73:175–177, 1959.
4) Deeley, T.J.: A clinical trial of synkavit in the treatment of carcinoma of the bronchus. Brit. J. Cancer, 16:387–389, 1962.
5) von Essen, C.F., Kligerman, M.M. and Calabresi, P.: Radiation and 5-Fluorouracil: A controlled clinical study. Radiology, 81: 1018–1027, 1963.
6) Figge, F.H.J., Weiland, G.S. and Manganiello, L.O.J.: Cancer detection and therapy. Affinity of neoplastic, embryonic, and traumatized tissues for porphyrins and metalloporphyrins. Proc. Soc. Exp. Biol. & Med., 68:640–641, 1948.
7) Fletcher, G.H., Suit, H.D., Howe, C.D., Samuels, M., Jesse, R.H. and Villareal, R.U.: Clinical method of testing radiation-sensitizing agents in squamous cell carcinoma. Cancer, 16: 355–363, 1963.
8) Friedman, M. and Daly, J.F.: Combined irradiation and chemotherapy in the treatment of squamous cell carcinoma of the head and neck. Amer. J. Roentgenol., 90:246–260, 1963.
9) Gollin, F.F., Ansfield, F.J. and Vermund, H.: Clinical studies of combined chemotherapy and irradiation in inoperable bronchogenic carcinoma. Amer. J. Roentgenol., 92:88–95, 1964.
10) Gollin, F.F., Ansfield, F.J., Curreri, A.R., Heidelberger, C. and Vermund, H.: Combined chemotherapy and

irradiation in inoperable bronchogenic carcinoma. Cancer, 15:1209–1217, 1962.
11) Hata, T. et al.: Mitomycin, A new antibiotic from streptomyces. I. J. Antibiotics, Series A., 9:141–146, 1956.
12) Ishida, T., Takahashi, N., Kondo, K. and Kimura, S.: Radiation therapy combined with Mitomycin C. Nipp. Act. Radiol., 22:847–853, 1962. (Japanese with English abstracts)
13) Johnson, R.E. and Brace, K.C.: Radiation response of Hodgkin's disease recurrent after chemotherapy. Cancer, 19:368–370, 1966.
14) Kaziwara, K., Watanabe, J., Kometa, T. and Usui, T.: Growth inhibiting activities of Chromomycin A_3 upon transplantable tumors. Annu. Rep. Takeda Res. Labor., 19:68–96, 1960. (Japanese with English abstracts)
15) Kligerman, M.M., Hellman, S., von Essen, C.F. and Bertino, J.R.: Sequential chemotherapy and radiotherapy. Radiology, 86:247–250, 1966.
16) Krabbenhoft, K.L. and Leucutia, T.: Combined roentgen therapy and nitrogen mustard in carcinoma of the lung as compared to other methods. Amer. J. Roentgenol., 79: 491–504, 1958.
17) Langdon, E.A., Ottoman, R.E., Rochlin, D.B. and Smart, C.R.: Early results of combined radiation and chemotherapy in treatment of malignant tumors. Radiology, 81:1008–1013, 1963.
18) Manheimer, L.H. and Vital, J.: Mitomycin C in the therapy of far-advanced malignant tumors. Cancer, 19: 207–212, 1966.
19) Matsunaga, F. et al.: Chemotherapy on gastric cancer. Naika (Internal Medicine), 17:1101–1115, 1966. (Japanese)
20) Mitchell, J.S., Brinkley, D. and Haybittle, J.L.: Clinical trial of radiosensitizers, including synkavit and oxygen inhaled at atmospheric pressure. Acta Radiol., 3:329–341, 1965.
21) Narabayashi, K., Kimura, S. and Ishida, T.: Current radiotherapy Jap. Med. J., 2184:29–43. 1966. (Japanese)
22) Plattner, P.A.: 1964 Chemotherapy of cancer. Amsterdam: Elsevier.
23) Schoeniger, E.L., Salerno, P.R. and Friedell, H.L.: Studies on the combined effect of Actinomycin D and X-radiation. Radiology, 79:310–315, 1962.
24) Sugawara, R. and Hata, T.: Mitomycin, a new antibiotic from streptomyces. II. Description of the strain. J. Antibiotics, Series A., 9:147–151, 1956.
25) Tazaki, Y., Furue, S., Tominaga, J. and Kozuki, H.: On the clinical effect of Hg-Hematoporphyrin. Gan no Rinsho (Clinic of Cancer), 5:755–758, 1959. (Japanese)
26) Teranaka, T.: Studies on antitumor activities of Mitomycin C. Osaka Shiritsu Daigaku Igaku Zasshi (J. Osaka City Med. Center), 7:272–279, 1958. (Japanese with English abstracts)
27) Whitehead, R.W. and Lanier, R.R.: The combined effect of a halogenated urethan derivative and x-rays on the growth of certain experimental tumors. Cancer Res.,14:418–422, 1954.