The University of Osaka
Institutional Knowledge Archive

Title	Pathophysiological evaluations of initial plaque development after heart transplantation via serial multimodality imaging and cytokine assessments
Author(s)	Shiraki, Tatsuya; Ichibori, Yasuhiro; Ohtani, Tomohito et al.
Citation	Journal of Heart and Lung Transplantation. 2022, 41(7), p. 877-885
Version Type	VoR
URL	https://hdl.handle.net/11094/90186
rights	This article is licensed under a Creative Commons Attribution 4.0 International License.
Note	

The University of Osaka Institutional Knowledge Archive : OUKA

https://ir.library.osaka-u.ac.jp/

The University of Osaka

The Journal of Heart and Lung Transplantation
http://www.jhltonline.org

ORIGINAL CLINICAL SCIENCE

Pathophysiological evaluations of initial plaque development after heart transplantation via serial multimodality imaging and cytokine assessments

Tatsuya Shiraki, MD,[a] Yasuhiro Ichibori, MD, PhD,[b] Tomohito Ohtani, MD, PhD,[a] Isamu Mizote, MD, PhD,[a] Hidetaka Kioka, MD, PhD,[a] Yasumasa Tsukamoto, MD, PhD,[a] Daisuke Nakamura, MD,[a] Kensuke Yokoi, MD,[a] Seiko Ide, MD, PhD,[a] Kei Nakamoto, MD,[a] Yasuharu Takeda, MD, PhD,[a] Jun-ichi Kotani, MD, PhD,[c] Shungo Hikoso, MD, PhD,[a] Yoshiki Sawa, MD, PhD,[d] and Yasushi Sakata, MD, PhD[a]

From the [a]Department of Cardiovascular Medicine, Osaka University Graduate School of Medicine, Suita, Japan; [b]Department of Cardiology, Osaka Police Hospital, Osaka, Japan; [c]Cardiovascular Institute of Therapeutic Evaluation and Creation, Sapporo Cardiovascular Clinic for Asia Medical Group, Sapporo, Japan; and the [d]Department of Cardiovascular Surgery, Osaka University Graduate School of Medicine, Suita, Japan.

KEYWORDS:
cardiac allograft vasculopathy; optical coherence tomography; intravascular ultrasound; interleukin-31; heart transplantation

BACKGROUND: Detailed morphological characteristics of de novo and donor-transmitted plaques and the association of serum T-lymphocyte cytokine levels with plaque progression of coronary allograft vasculopathy within 1 year after heart transplantation are unknown.

METHODS: In this retrospective analysis of data in a prospectively maintained database, 40 heart transplant recipients were included. We performed serial 3 vessel optical coherence tomography and intravascular ultrasound analyses, at the 8 week (baseline) and 12 month post-transplantation follow-ups, and serum cytokine measurements (n = 23). The correlation between serum cytokines and Δplaque burden (between baseline and follow-up) was evaluated depending on plaque morphology.

RESULTS: Thirteen de novo plaques (maximum intimal thickness ≥0.5 mm at the 12 month follow-up without plaques at baseline) were identified in 8 recipients, and 31 donor-transmitted plaques (maximum intimal thickness ≥0.5 mm at baseline) were detected in 17 recipients. Compared with donor-transmitted plaques, the Δplaque burden in the de novo plaques, with mainly fibrous morphology, was high (38.8% [29.6%−41.2%] vs 8.7% [1.33%−13.6%], $p < 0.001$). Stratification of the morphology of donor-transmitted plaques revealed that the Δplaque burden in fibrous plaques (10.6% [7.0%−18.0%]) was similar to that in fibroatheroma (10.3% [8.7%−23.8%]). Serum interleukin-31 levels at baseline correlated with fibrous plaque proliferation ($r = 0.73$, $p = 0.007$) even under immunosuppressive conditions, whereas other cytokines (interleukin-1β, interleukin-17, and interferon-gamma) were mostly undetectable.

Conflicts of Interest: The authors declare that they have no conflicts of interest.

Reprint requests: Tomohito Ohtani, MD, PhD, Department of Cardiovascular Medicine, Osaka University Graduate School of Medicine, 2-2 Yamadaoka, Suita, Osaka 565-0871, Japan, Telephone: +81-6-6879-3640; Fax: +81-6-6879-3639.
E-mail address: ohtani@cardiology.med.osaka-u.ac.jp

1053-2498/$ - see front matter © 2022 The Author(s). Published by Elsevier Inc. on behalf of International Society for Heart and Lung Transplantation. This is an open access article under the CC BY license (http://creativecommons.org/licenses/by/4.0/)
https://doi.org/10.1016/j.healun.2022.03.007

CONCLUSIONS: Intimal fibrous proliferation contributed to the progression of donor-transmitted and de novo plaques. Serum interleukin-31 levels at baseline may contribute to intimal fibrous proliferation within 1 year after heart transplantation.
J Heart Lung Transplant 2022;41:877−885
© 2022 The Author(s). Published by Elsevier Inc. on behalf of International Society for Heart and Lung Transplantation. This is an open access article under the CC BY license (http://creativecommons.org/licenses/by/4.0/)

Despite progress in immunosuppressive therapy and patient management after heart transplantation (HTx), cardiac allograft vasculopathy (CAV) remains a hurdle to successful long-term outcomes for organ recipients. CAV accounts for up to 1 in 8 deaths within a year of HTx,[1] and most intimal thickenings occurred during the first year after HTx.[2] In fact, coronary arterial intimal thickening ≥0.5 mm, identified as a plaque, within a year of HTx appears to be a reliable marker for long-term outcomes.[3]

In a study of serial intravascular ultrasound (IVUS) examinations performed within 12 months after HTx, de novo plaques had a more diffuse, circumferential pattern than donor-transmitted plaques,[4] suggesting pathobiological differences. Optical coherence tomography (OCT)[5] has revealed that macrophage accumulation and intimal microchannels are associated with CAV severity in the stable phase after HTx.[6,7] T-lymphocyte infiltration of the smooth muscle cell-rich fibrotic intima has been discovered in the early phase after HTx,[8] and T-lymphocyte infiltration may be involved in immune vasculitis, including Takayasu disease.[9-11] However, the relationship between these changes in the immune system and CAV has not been well elucidated, and we are not aware of any study in which OCT and IVUS have been comprehensively and serially used to evaluate the association between plaque progression and morphology in de novo and donor-transmitted plaques within 12 months of HTx.

Our aim was to elucidate the associations between early plaque progression, plaque morphologies, and serum cytokines related to T-lymphocytes. The primary objective of this study was to identify the morphological characteristics using OCT in de novo and donor-transmitted plaques identified using serial IVUS examinations. The secondary objective was to identify the serum cytokines that are associated with intimal proliferation early after HTx.

Materials and methods

Study design and population

The study participants were selected from a prospective observational cohort comprising patients who underwent angiography and serial 3 vessel OCT and IVUS evaluation at 8 weeks (baseline) and 12 months (follow-up) after HTx in Osaka University Hospital between August 2011 and December 2016. Of the 50 consecutive patients, 8 with insufficient OCT data and 2 who died within 12 months after HTx were excluded, leaving 40 patients.

Information on demographics, medical history, comorbidities, laboratory test results, and medication use at catheterization were collected at baseline and at follow-up. Medication regimens comprising prednisolone, tacrolimus, mycophenolate mofetil, aspirin, and statin were started in the acute phase and were switched to everolimus at the physician's discretion based on the surgical wound, renal function, and plaque burden of the coronary artery. This study was performed in accordance with the principles underlying the Declaration of Helsinki, and the study protocol was approved by the Osaka University Hospital ethics committee (No. 12301-4). Written informed consent was obtained from all patients. The study findings were reported in conformance with the Strengthening the Reporting of Observational Studies in Epidemiology (STROBE) guidelines.

Imaging procedure

The details of the IVUS examination and OCT imaging procedures are described in the supplemental method. The abovementioned procedures were repeated in the left anterior descending artery (LAD), left circumflex artery (LCx), and right coronary artery (RCA). All images were stored digitally for offline analysis.

Imaging data analysis

Quantitative IVUS analysis was performed by using certified offline software (QIVUS, Medis Medical Imaging, Leiden, Netherlands). The proximal and distal ends of the plaque were determined, the lumen and external elastic membrane (EEM) at the plaque were automatically traced with minimal manual modifications, the minimum lumen area was automatically identified, and the parameters were obtained. The parameters were as follows: maximum intimal thickness (MIT), lumen cross-sectional area (CSA), EEM CSA, and plaque burden [(EEM CSA − lumen CSA)/EEM CSA × 100], and the Δplaque burden (plaque burden at follow-up − plaque burden at baseline) was evaluated. A donor-transmitted plaque was defined as an MIT ≥0.5 mm at 8 weeks;[4] a de novo plaque was defined as an MIT ≥0.5 mm at the 12 month follow-up and the absence of a plaque in that lesion at 8 weeks[4] (Figure 1). Plaques were considered independent if there was an intervening gap of >3 mm between them. The plaque lesion length was measured and the minimum lumen CSA site within the plaque lesion was analyzed at the 12 month follow-up evaluation. For the 8 week analysis, segments and cross-sections corresponding to the follow-up study were identified. Angiographic, IVUS, and OCT landmarks, such as side branches, the pericardium, and cardiac veins were used for matching of the sites.

Qualitative OCT analysis was performed by using an offline review workstation (LightLab Imaging, Westford, MA, USA). Plaques were classified as fibrous plaque, fibrocalcific plaque, and fibroatheroma based on the International Working Group for Intravascular Optical Coherence Tomography consensus standards.[12] Macrophage accumulation was defined as signal-rich attenuated regions within the intimal layer and a signal intensity exceeding that of adjacent fibrotic tissue.[12] Intimal microchannels were defined as small tubular structures with a diameter ≤200 μm,

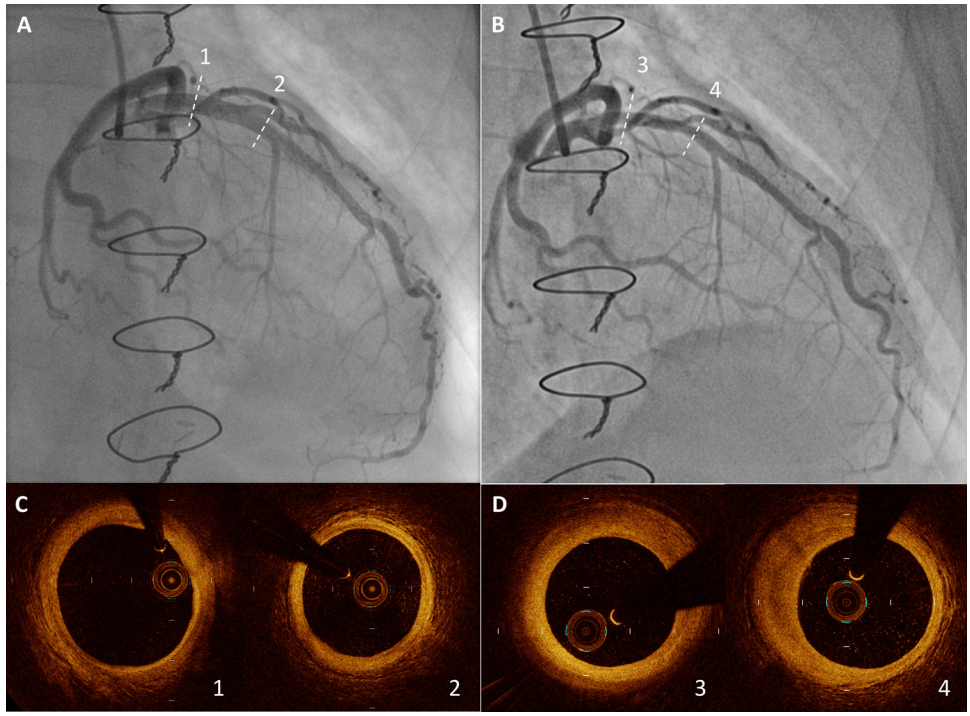

Figure 1 Representative coronary angiography and optical coherence tomography (OCT) images of the development of de novo plaques.Coronary angiography at 8 weeks (A) and 12 months (B) after heart transplantation. Cross-sectional OCT images from proximal to distal regions correspond to the white lines on the coronary angiogram. OCT revealed no plaques at 8 weeks (C), and de novo fibrous plaques were discovered at the 12 month follow-up (D).

spanning the neointimal tissue, without a connection to the vessel lumen, recognizable on more than 3 contiguous frames.[7]

Serum cytokine evaluation

Peripheral blood samples of 23 patients were collected in a standard tube, the serum was obtained by centrifugation, and aliquots were immediately stored at −80°C until the assay was performed. Serum levels of T-cell-related cytokines (interferon-gamma [IFNγ], tumor necrosis factor-alpha [TNFα], interleukin [IL]-1β, IL-4, IL-6, IL-10, IL-17A, IL-17F, IL-21, IL-22, IL-23, IL-25, IL-31, IL-33, and CD40 ligand-soluble fraction [sCD40L]) were measured with a commercial bead-based multiplex assay (Bio-Plex Pro human Th17 cytokine assays, Bio-Rad Laboratories, Inc., Hercules, CA, USA) according to the manufacturer's instructions. Results are expressed in pg/mL.

Statistical analysis

Continuous variables are expressed as medians and interquartile ranges and categorical variables were expressed as frequencies and percentages. The Mann−Whitney U and Kruskal−Wallis tests were used to compare continuous variables, whereas the chi-square test was used to compare categorical variables. The Wilcoxon rank-sum test was used to compare median values for IVUS quantitative parameters. Pearson's correlation (r) test was utilized to analyze the correlation between cytokine concentrations and the Δplaque burden. The inter- and intra-observer intraclass correlation coefficients (ICCs) for the measurement of the plaque burden were determined for a subset of 10 plaques. The estimated inter- and intra-observer ICCs were 0.996 (0.985−0.999) and 0.997 (0.989−0.999), respectively. Cohen's κ test of concordance was used to quantify the agreement between the OCT characteristic assessments of 2 independent observers (T.S. and D.N.). In this study, the mean κ-value of the OCT diagnostic assessment was 0.81 (0.74−0.87). All analyses were 2 tailed; $p < 0.05$ was considered statistically significant. All statistical analyses were performed with IBM SPSS Statistics version 27.0.1 (IBM Corp., Armonk, NY, USA).

Results

The HTx recipient characteristics are summarized in Table 1. Blood pressure, cholesterol status, and glycated hemoglobin level were well controlled in all recipients at baseline and follow-up.

Systemic determinants of de novo plaque development

Table 1 presents a comparison of characteristics between recipients with at least 1 de novo plaque (n = 8) and recipients without de novo plaques (n = 32). HTx recipients with de novo plaques had more ischemic cardiomyopathy (ICM) etiology as the primary disease and a longer cold ischemic time during the HTx. No significant inter-group differences were observed in the laboratory test results or medication use.

Table 1 Baseline Characteristics of Study Participants

		De novo plaque		
	Overall (n = 40)	Yes (n = 8)	No (n = 32)	p-value
Age, yrs	38 (30–49)	48 (38–54)	36 (30–47)	0.13
Male	25 (63)	7 (88)	18 (56)	0.10
BMI	20 (18–23)	19 (18–21)	20 (19–23)	0.42
Hypertension	1 (3)	0 (0)	1 (3)	0.61
Dyslipidemia	4 (10)	1 (13)	3(9)	0.79
Diabetes mellitus	4 (10)	0 (0)	4 (13)	0.29
Reason for HTx				
Dilated cardiomyopathy	22 (55)	4 (50)	18 (56)	0.75
Hypertrophic cardiomyopathy	5 (13)	0 (0)	5 (16)	0.23
Ischemic cardiomyopathy	7 (18)	4 (50)	3 (9)	<0.01
Others	6 (15)	0 (0)	6 (19)	0.18
HTx-specific factor				
Donor age, yrs	44 (33–50)	45 (40–53)	43 (30–49)	0.28
Cold ischemic time, min	225 (188–237)	240 (233–246)	220 (180–232)	0.02
Cytomegalovirus infection	3 (8)	0 (0)	3 (9)	0.37
ACR (≥2R)	2 (5)	0 (0)	2 (6)	0.47
AMR	2 (5)	0 (0)	2 (6)	0.47
Donor-transmitted plaque at baseline	17 (43)	3 (38)	14 (44)	0.75
Baseline (8 weeks after HTx)				
Systolic BP, mmHg	110 (103–120)	116 (96–119)	110 (103–122)	0.61
Diastolic BP, mmHg	66 (60–70)	63 (60–69)	66 (60–70)	0.70
LDL-C, mg/dL	82 (68–100)	79 (72–103)	82 (67–100)	0.86
HDL-C, mg/dL	55 (46–64)	56 (44–60)	54 (47–65)	0.78
HbA1c, %	5.4 (5.2–5.8)	5.6 (5.4–5.7)	5.4 (5.2–5.9)	0.78
C-reactive protein, mg/dL	0.04 (0.04–0.06)	0.06 (0.04–0.11)	0.04 (0.04–0.05)	0.28
BNP, pg/mL	123 (81–227)	118 (97–127)	140 (76–231)	0.58
Prednisolone	40 (100)	8 (100)	32 (100)	-
Tacrolimus	32 (80)	7 (88)	25 (78)	0.55
Cyclosporine	1 (3)	0 (0)	1 (3)	0.61
Mycophenolate mofetil	39 (98)	8 (100)	31 (97)	0.61
Everolimus	5 (13)	0 (0)	5 (16)	0.23
Aspirin	38 (95)	8 (100)	30 (94)	0.47
Statin	35 (88)	6 (75)	29 (91)	0.23
Follow-up (12 months after HTx)				
Systolic BP, mmHg	114 (104–124)	113 (103–123)	114 (106–124)	0.83
Diastolic BP, mmHg	65 (58–74)	74 (65–77)	64 (58–73)	0.25
LDL-C, mg/dL	81 (70–96)	86 (71–94)	79 (70–96)	0.99
HDL-C, mg/dL	59 (48–67)	57 (52–63)	59 (45–67)	0.96
HbA1c, %	5.8 (5.4–6.1)	5.7 (5.5–6.1)	5.9 (5.4–6.2)	0.88
C-reactive protein, mg/dL	0.04 (0.04–0.07)	0.04 (0.04–0.05)	0.04 (0.04–0.08)	0.83
BNP, pg/mL	43 (28–77)	41 (34–62)	43 (25–77)	0.99
Prednisolone	39 (98)	8 (100)	31 (97)	0.61
Tacrolimus	34 (85)	8 (100)	26 (81)	0.18
Cyclosporine	4 (10)	0 (0)	4 (13)	0.29
Mycophenolate mofetil	17 (43)	4 (50)	13 (41)	0.63
Everolimus	28 (70)	5 (63)	23 (72)	0.61
Aspirin	35 (88)	8 (100)	27 (84)	0.23
Statin	38 (95)	7 (88)	31 (97)	0.28

ACR ,acute cellular rejection ≥2R of the International Society for Heart Lung Transplantation grading system within 1 year after heart transplantation; AMR, antibody-mediated rejection within 1 year after heart transplantation; BMI = body mass index (calculated as weight in kilograms divided by square of height in meters); BNP, brain natriuretic peptide; BP, blood pressure; HTx, heart transplantation; HDL-C = high-density lipoprotein cholesterol; LDL-C, low-density lipoprotein cholesterol; HbA1c, glycated hemoglobin.

Values are number (%) or median (interquartile range).

Plaque characteristics determined with serial IVUS and OCT

There were 3 hypoplastic coronary arteries in 3 participants, an inability to advance imaging catheters due to tortuosity in 5 coronary arteries, and inadequate images in 6 coronary arteries. Finally, 13 de novo plaques in 11 arteries in 8 recipients as well as 31 donor-transmitted plaques in 27 arteries in 17 recipients were identified in all 106 arteries. Serial changes in MIT in donor-transmitted and de novo plaques are presented in Figure 2A-C. IVUS and OCT characteristics are summarized in Table 2. The de novo plaques had a large increase in MIT compared with donor-transmitted plaques and their changes were significantly greater, as well as the Δplaque burden. The incidence of de novo plaques at 12 months was not high in vessels with donor-transmitted plaques compared to that in vessels without donor-transmitted plaques (LAD, 0% [0/16 vessels] vs 22% [5/23 vessels]; $p = 0.07$; all 3 vessels, 4% [1/27 vessels] vs 13% [10/75 vessels], $p = 0.28$). There were no regional differences in the development of de novo plaques and the Δplaque burden in terms of both LAD/LCx/RCA coronary involvement and the proximal/middle portion of vessels (Supplemental Table). The Δplaque burden of donor-transmitted plaques did not differ according to vessel or location.

In the 13 de novo plaques, the main morphologies observed with OCT were fibrous plaques (92.3%, 12/13), followed by fibroatheroma (7.7%, 1/13), and the Δplaque burdens of fibrous plaques and fibroatheroma were 36.3% [29.1%−41.2%] and 39.8%, respectively. In 31 donor-transmitted plaques, the prevalence of fibrous plaque, fibroatheroma, and fibrocalcific plaques was 48% (15/31), 29% (9/31), and 23% (7/31), respectively. The Δplaque burden of fibrous plaques (10.6% [7.0%−18.0%]) was similar to that of fibroatheroma (10.3% [8.7%−23.8%], $p = 0.96$) but significantly higher than that of fibrocalcific plaques (1.5% [−0.1% to 3.7%], $p = 0.01$). At the 12 month follow-up, the increase in patients with an MIT of ≥0.5 mm was not statistically significant; however, it tended to differ depending on plaque morphology (fibrous plaques: 41% [11/27], fibroatheroma: 20% [2/10], and fibrocalcific plaques: 0% [0/7]; $p = 0.08$) and did not differ for donor-transmitted plaques (fibrous plaques: 7% [1/15], fibroatheroma: 1% [1/9], and fibrocalcific plaques: 0% [0/7]; $p = 0.69$). The prevalence of macrophage accumulation was lower in de novo plaques than in donor-transmitted plaques (7.7% [1/13] vs 67.7% [21/31], $p < 0.01$). Macrophage accumulation was not observed in any de novo fibrous plaques; however, it was highly prevalent in donor-transmitted plaques of each morphology [fibrous plaque, 60% (9/15); fibroatheroma, 100% (9/9) and fibrocalcific plaque, 42.8% (3/7)]. The presence of macrophage accumulation in donor-transmitted plaques at follow-up was not associated with the Δplaque burden ($p = 0.82$).

The prevalence of intimal microchannels tended to differ between de novo and donor-transmitted plaques at 12 months (38.5% [5/13] vs 67.7% [21/31], $p = 0.10$). In donor-transmitted plaques, the prevalence of intimal microchannels at follow-up was 73.3% (11/15) in fibrous plaques, 77.7% (7/9) in fibroatheroma, and 42.8% (3/7) in fibrocalcific plaques; it was unassociated with the Δplaque burden ($p = 0.88$).

Serum cytokine measurements

Serum cytokine concentrations were measured in 23 patients (4 patients with and 19 without de novo plaques, respectively) both at baseline and at follow-up. Four cytokines (IL-6, IL-31, sCD40L, and TNFα) were detectable even in immunosuppressive conditions, whereas other cytokines (IFNγ, IL-1β, IL-4, IL-10, IL-17A, IL-17F, IL-21, IL-22, IL-23, IL-25, and IL-33) were not detected. As summarized in Table 3, serum IL-31 concentrations at baseline were significantly higher in recipients with de novo plaque development than in those without de novo plaque development ($p < 0.01$), although this difference was not significant at follow-up ($p = 0.61$).

Per-plaque analysis was performed to determine the correlation between serum IL-31 concentrations at baseline

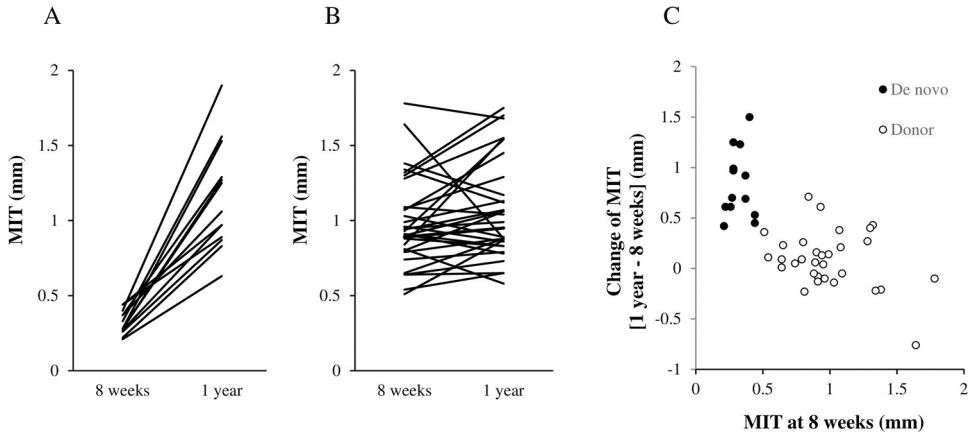

Figure 2 Maximum intimal thickness and its change from 8 weeks to 12 months after heart transplantation.Serial changes of maximum intimal thickness (MIT) in de novo (A) and donor-transmitted (B) plaques are illustrated. The MIT at 8 weeks was correlated with the change of MIT from 8 weeks to 12 months (C).

Table 2 Findings of Intravascular Ultrasound and Optical Coherence Tomography

	De novo plaques (n = 13)	Donor-transmitted plaques (n = 31)	p-value
IVUS findings at 8 weeks after HTx			
Lesion length, mm	-	11.6 (7.5 – 30.5)	-
MIT, mm	0.28 (0.27–0.37)	0.93 (0.81–1.09)	<0.001
Lumen CSA, mm2	15.8 (12.5–19.6)	9.7 (6.1–14.1)	<0.01
EEM CSA, mm2	17.8 (15.8–20.4)	17.2 (12.7–19.3)	0.43
Plaque burden, %	11.4 (8.8–17.1)	37.0 (27.1–52.9)	<0.001
IVUS findings at 12 months after HTx			
Lesion length, mm	8.1 (7.7–11.8)	14.7 (9.2–31.6)	0.03
MIT, mm	1.06 (0.89–1.29)	0.99 (0.85–1.23)	0.43
Lumen CSA, mm2	7.9 (5.7–8.6)	6.5 (4.5–11.6)	0.47
EEM CSA, mm2	14.3 (11.8–18.2)	14.2 (11.1–17.9)	0.79
Plaque burden, %	48.5 (40.5–55.1)	52.7 (36.1–61.5)	0.62
Changes between 8 weeks and 12 months after HTx			
Δ MIT, mm	0.7 (0.61–0.99)	0.09 (-0.09–0.25)	<0.001
Δ MIT ≥0.5 mm, %	11 (85)	2 (6)	<0.001
Δ Lumen CSA, mm2	-8.17 (-9.47–-4.37)	-1.79 (-3.22–-1.02)	<0.001
Δ EEM CSA, mm2	-1.87 (-4.11–-0.04)	-1.25 (-2.48–-0.33)	0.60
Δ Plaque burden, %	38.8 (29.6–41.2)	8.7 (1.33–13.6)	<0.001
OCT findings			
Morphology			0.02
Fibrous plaque	12 (92)	15 (48)	
Fibroatheroma	1 (8)	9 (29)	
Fibrocalcific plaque	0 (0)	7 (23)	
Macrophage accumulation	1 (8)	21 (68)	<0.01
Intimal microchannel	5 (39)	21 (68)	0.10

CSA, cross-sectional area; EEM, external elastic membrane; HTx, heart transplantation; IVUS, intravascular ultrasound; MIT, maximum intimal thickness; OCT, optical coherence tomography.

Values are number (%) or median (interquartile range).

and the Δplaque burden of de novo and donor-transmitted plaques (Figure 3). A positive correlation was discovered between serum IL-31 concentrations at baseline and the Δplaque burden for overall plaques (Figure 3A); however, the separate Δplaque burdens of de novo and donor-transmitted plaques were not correlated with serum IL-31 concentrations at baseline (Figure 3B). The per-plaque morphological assessment revealed a correlation between the serum IL-31 concentration at baseline and the Δplaque burden of fibrous plaques (Figure 3C), whereas no significant correlation was observed between serum IL-31 concentration and the Δplaque burden of fibroatheroma or fibrocalcific plaques. The statistical power to detect the influence of correlation between the serum IL-31 concentration at baseline and the Δplaque burden of fibrous plaques, with a 2 sided significance level of 5%, was satisfactory (0.83).

Discussion

This study has 3 major findings. First, serial IVUS and OCT evaluations revealed that, within 12 months of HTx, progression of the de novo plaques—with a mostly fibrous morphology and lower degrees of macrophage accumulation than donor-transmitted plaques—was significantly greater than that of donor-transmitted plaques, which comprised various morphologies—fibrous (48%), fibroatheromatous (29%), and fibrocalcific (23%)—accompanied by non-negligible macrophage accumulation. The incidence of de novo plaques at the 12 month follow-up was not high in vessels with existing donor-transmitted plaques compared to that in vessels without donor-transmitted plaques at 8 weeks. Second, when assessing only donor-transmitted plaques, fibrous plaques progressed similarly to fibroatheroma, unlike those in general atherosclerosis. Finally, exploratory comprehensive cytokine assays suggested that the serum IL-31 concentration at 8 weeks after HTx is associated with fibrous plaque proliferation, even under immunosuppressive conditions.

Autopsy studies have revealed that the morphology of CAV lesion comprises a predominantly fibrous structure composed of smooth muscle cells and connective tissue with lymphocytic infiltration, especially in the early post-HTx stages,[13] as well as the presence of macrophage infiltration, but no evidence of lipid-rich foamy macrophage deposition in the intima.[8] In this study, macrophage accumulation[14] was rarely observed in de novo plaques, whereas it was commonly observed in donor-transmitted plaques, indicating the possibility of a differing pathophysiology depending on plaque type. Antibody-mediated rejection (AMR) induces fibrous proliferation with inflammation,[15] occurring in 2 patients with donor-transmitted plaques in this study. No association between AMR and macrophage accumulation or plaque progression was detected in donor-

Table 3 Serum Cytokine Levels at Baseline and at Follow-Up After Heart Transplantation

		De novo plaque		
	Overall (n = 23)	Yes (n = 4)	No (n = 19)	p-value
Baseline (8 weeks after HTx)				
IL-6, pg/mL	1.5 (1.0–3.1)	2.1 (1.4–3.9)	1.2 (1.0–2.1)	0.51
IL-31, pg/mL	233 (93–306)	405 (361–490)	135 (72–265)	<0.01
sCD40L, pg/mL	244 (182–362)	377 (288–474)	213 (163–264)	0.12
TNFα, pg/mL	3.9 (2.8–9.0)	4.5 (3.0–8.2)	3.9 (3.6–8.1)	0.85
Follow-up (12 months after HTx)				
IL-6, pg/mL	2.3 (1.1–4.0)	2.2 (1.7–6.0)	2.0 (1.1–4.8)	0.73
IL-31, pg/mL	253 (185–342)	295 (237–339)	250 (156–302)	0.61
sCD40L, pg/mL	270 (183–383)	237 (206–336)	285 (193–317)	0.97
TNFα, pg/mL	4.3 (2.0–7.2)	5.8 (2.4–15.8)	4.3 (2.4–5.8)	0.61

HTx, heart transplantation; IL, interleukin; sCD40L, CD40 ligand soluble fraction; TNFα, tissue necrosis factor α.
Values are median (interquartile range).

transmitted plaques; however, our sample size was small. Conversely, acute cellular rejection (ACR, ≥2R) occurred in 2 other patients with donor-transmitted plaques, which was associated with macrophage accumulation and intimal microchannels but not plaque progression. These different OCT characteristics may relate to the presence of donor-transmitted atherosclerosis, AMR, or ACR, which may not always reflect the initial features of CAV.

Donor-transmitted atherosclerosis is a known risk factor of CAV progression.[16,17] However, we did not observe a

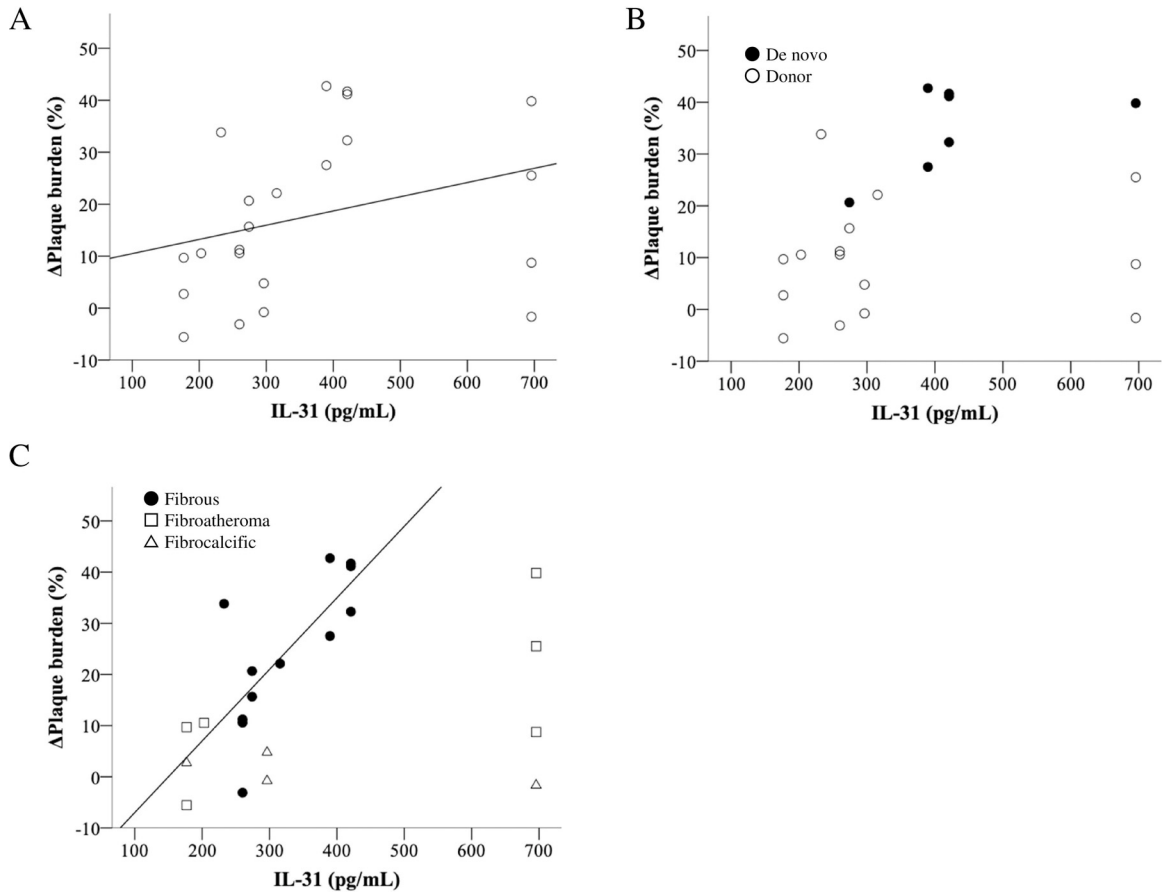

Figure 3 Per-plaque analyses for the relationship between the Δplaque burden and serum interleukin-31 (IL-31) concentration at baseline after heart transplantation. (A) The correlation between the serum IL-31 concentration at baseline and the Δplaque burden of donor-transmitted and de novo plaques (r = 0.43, p = 0.045). (B) Subgroups categorized according to de novo (r = 0.36, p = 0.43) and donor-transmitted (r = 0.16, p = 0.56) plaques. (C) Subgroups categorized according to plaque morphology (fibrous plaques [r = 0.73, p = 0.007; solid line], fibroatheroma [r = 0.70, p = 0.13], and fibrocalcific plaques [r = −0.66, p = 0.34]).

positive correlation between the development of de novo plaques and vessels with donor-transmitted atherosclerosis, which may have been because of the small sample size and the different definitions of de novo plaques. Nevertheless, the discordance between our results and previous observations in donor-transmitted fibroatheroma[18] led to a novel hypothesis that the milder progression of donor-transmitted plaques than of de novo plaques may be related to the limited space afforded by the donor-transmitted mature fibrous tissue, lipid core, and/or calcification, preventing de novo fibrous proliferation by pleomorphic smooth muscle cells and abundant proteoglycan. However, adopting the definition of lesion progression as reported for stable angina pectoris (an IVUS lumen area decrease >0.5 mm^2 within a year)[19] in this study revealed a high incidence (81%, 25/31) of plaque progression in donor-transmitted plaques, despite well-managed atherosclerotic risks. Fibrous proliferation, which contributed to a higher increase in plaque burden than in atherosclerosis, was involved in the progression of donor-transmitted fibroatheroma and fibrous plaques but not calcified plaques. Based on the analysis by stratification according to plaque morphology and everolimus usage in the initial year (Supplemental Figure), it may be inferred that everolimus might exert a preventive effect on plaque progression, that differs with plaque characteristics. Reportedly, the beneficial effect of everolimus on CAV progression with no (early) or a mild (late post-HTx stage) increase in inflammatory tissue components (calcified and necrotic tissue) and a mild decrease in fibrous proliferation differed depending on the presence or absence of donor-transmitted atherosclerosis.[20-22] Similarly, there were no or mild changes in fibroatheroma and calcified plaques in this study. However, its effect on de novo fibrous plaques was small compared to that in previous reports. According to discordant results among previous studies,[20-22] this difference may be associated with the time window in which everolimus was initiated (median, 12.6 weeks after HTx in this study), with its earlier initiation possibly having a larger effect on de novo fibrous proliferation. However, as this was an observational study and attending physicians could switch the treatment to everolimus because of, for example, intimal thickening at 8 weeks after transplantation, it was difficult to fully evaluate the effect of everolimus on CAV in this study. Further research with controlled medication use is needed.

The serum IL-31 concentration at baseline was positively correlated with fibrous plaque proliferation under immunosuppressive conditions, whereas concentrations of other cytokines, such as IL-1β, IL-6, IL-17, and IFNγ, were not. In a study of the association of cytokines with the development of CAV at a mean of 12 years after HTx, none of the cytokines were associated with the development of CAV.[23] In the present study, there was no association between serum IL-31 concentration and plaque progression at the 12 month follow-up. This may indicate the importance of defining a time window in which to detect cytokines according to immunological inflammation. IL-31 is involved in inflammation associated with Th2 cells.[24] Notably, in patients with Kawasaki disease, the appearance of coronary artery lesions is reportedly associated with an elevated serum IL-31 concentration.[25] OCT evaluations in Kawasaki disease revealed that intimal fibrotic hyperplasia is present in angiographically normal coronary arteries,[26,27] which supports the hypothesis that IL-31 may be involved in CAV progression as well as in Kawasaki disease.

Limitations

This study had several limitations. First, its single-center design and small sample limited its statistical power, possibly resulting in type II errors and hindering the use of multivariable analysis. Among cases in which serum cytokine concentrations could be measured, de novo plaques were observed in only 4, which was insufficient for per-patient analysis. Although the association of serum IL-31 with fibrous plaque proliferation was evaluated with sufficient statistical power, data derived from larger samples are necessary. Second, only Japanese patients were included, and the prevalence of ICM as a primary disease in HTx recipients was relatively low; therefore, the results of this study may not be generalizable to patients in other countries. Third, we did not evaluate the left main coronary trunk or distal segments. Finally, we did not verify the expression of IL-31 or IL31-receptor A in coronary artery tissue, and this is a subject for future investigation to clarify the mechanism of CAV.

In conclusion, intimal fibrous proliferation contributed to the progression of donor-transmitted and de novo plaques. The serum IL-31 concentration at baseline was associated with fibrous proliferation, indicating that serum IL-31 is a potential biomarker or a possible therapeutic target in CAV.

Author contributions

TS, YI, TO, YT, JK, and YS: research conceptualization and design; TS, YI, TO, IM, HK, TY, DN, KY, SI, KN, JK, YS, and YS: data collection; TS, TO, IM, HK, YT, DN, YT, SH, and YS: analysis and interpretation; TS and TO: writing of the paper.

Disclosure statement

The authors have no relationships relevant to the contents of this paper to disclose.

This work was supported by JSPS KAKENHI (Grant Number 17K16005). The authors thank Miyo Yasui for her assistance in collecting blood samples, Kaori Kubota for her assistance in clinical data collection, and Ryotaro Saita and Tohoharu Sato for statistical advice.

Supplementary materials

Supplementary material associated with this article can be found in the online version at https://doi.org/10.1016/j.healun.2022.03.007.

References

1. Lund LH, Edwards LB, Kucheryavaya AY, et al. The registry of the international society for heart and lung transplantation: thirty-second official adult heart transplantation report−2015; focus theme: early graft failure. J Heart Lung Transplant 2015;34:1244-54.
2. Tsutsui H, Ziada KM, Schoenhagen P, et al. Lumen loss in transplant coronary artery disease is a biphasic process involving early intimal thickening and late constrictive remodeling: results from a 5-year serial intravascular ultrasound study. Circulation 2001;104:653-7.
3. Kobashigawa JA, Tobis JM, Starling RC, et al. Multicenter intravascular ultrasound validation study among heart transplant recipients: outcomes after five years. J Am Coll Cardiol 2005;45:1532-7.
4. Kapadia SR, Nissen SE, Ziada KM, et al. Development of transplantation vasculopathy and progression of donor-transmitted atherosclerosis: comparison by serial intravascular ultrasound imaging. Circulation 1998;98:2672-8.
5. Prati F, Regar E, Mintz GS, et al. Expert review document on methodology, terminology, and clinical applications of optical coherence tomography: physical principles, methodology of image acquisition, and clinical application for assessment of coronary arteries and atherosclerosis. Eur Heart J 2010;31:401-15.
6. Clemmensen TS, Holm NR, Eiskjær H, et al. Layered fibrotic plaques are the predominant component in cardiac allograft vasculopathy: systematic findings and risk stratification by OCT. JACC Cardiovasc Imaging 2017;10:773-84.
7. Ichibori Y, Ohtani T, Nakatani D, et al. Optical coherence tomography and intravascular ultrasound evaluation of cardiac allograft vasculopathy with and without intimal neovascularization. Eur Heart J Cardiovasc Imaging 2016;17:51-8.
8. Devitt JJ, Rice A, McLean D, Murray SK, Hirsch GM, Lee TD. Impact of donor benign intimal thickening on cardiac allograft vasculopathy. J Heart Lung Transplant 2013;32:454-60.
9. Saadoun D, Garrido M, Comarmond C, et al. Th1 and Th17 cytokines drive inflammation in Takayasu arteritis. Arthritis Rheumatol 2015;67:1353-60.
10. Guo MM-H, Tseng W-N, Ko C-H, et al. Th17- and Treg-related cytokine and mRNA expression are associated with acute and resolving Kawasaki disease. Allergy 2015;70:310-8.
11. Deng J, Younge BR, Olshen RA, Goronzy JJ, Weyand CM. Th17 and Th1 T-cell responses in giant cell arteritis. Circulation 2010;121:906-15.
12. Tearney GJ, Regar E, Akasaka T, et al. Consensus standards for acquisition, measurement, and reporting of intravascular optical coherence tomography studies: a report from the International Working Group for Intravascular Optical Coherence Tomography Standardization and Validation. J Am Coll Cardiol 2012;59:1058-72.
13. Huibers MN, Vink A, Kaldeway J, et al. Distinct phenotypes of cardiac allograft vasculopathy after heart transplantation: a histopathological study. Atherosclerosis 2014;236:353-9.
14. Phipps JE, Vela D, Hoyt T, et al. Macrophages and intravascular OCT bright spots: a quantitative study. JACC Cardiovasc Imaging 2015;8:63-72.
15. Loupy A, Toquet C, Rouvier P, et al. Late failing heart allografts: pathology of cardiac allograft vasculopathy and association with antibody-mediated rejection. Am J Transplant 2016;16:111-20.
16. Yamasaki M, Sakyrai R, Hirohata A, et al. Impact of donor-transmitted atherosclerosis on early cardiac allograft vasculopathy: new findings by three-dimensional intravascular ultrasound analysis. Transplantation 2011;91:1406-11.
17. Watanabe T, Seguchi O, Yanase M, et al. Donor-transmitted atherosclerosis associated with worsening cardiac allograft vasculopathy after heart transplantation: serial volumetric intravascular ultrasound analysis. Transplantation 2017;101:1310-9.
18. Yokoi K, Otsuka F, Mizote I, et al. In vivo intracoronary imaging assessment of cardiac allograft vasculopathy with histopathologic confirmation. JACC Cardiovasc Interv 2020;13:2305-7.
19. Yamamoto MH, Yamashita K, Matsumura M, et al. Serial 3-vessel optical coherence tomography and intravascular ultrasound analysis of changing morphologies associated with lesion progression in patients with stable angina pectoris. Circ Cardiovasc Imaging 2017;10:e006347.
20. Arora S, Andreassen AK, Karason K, et al. Effect of everolimus initiation and calcineurin inhibitor elimination on cardiac allograft vasculopathy in de novo heart transplant recipients. Circ Heart Fail 2018;11:e004050.
21. Arora S, Erikstad I, Ueland T, et al. Virtual histology assessment of cardiac allograft vasculopathy following introduction of everolimus −results of a multicenter trial. Am J Transplant 2012;12:2700-9.
22. Arora S, Ueland T, Wennerblom B, et al. Effect of everolimus introduction on cardiac allograft vasculopathy−results of a randomized, multicenter trial. Transplantation 2011;92:235-43.
23. Przybylek B, Boethig D, Neumann A, et al. Novel cytokines score and coronary allograft vasculopathy. Am J Cardiol 2019;123:1114-9.
24. Dillon SR, Sprecher C, Hammond A, et al. Interleukin 31, a cytokine produced by activated T cells, induces dermatitis in mice. Nat Immunol 2004;5:752-60.
25. Tseng WN, Lo MH, Guo MM, Hsieh KS, Chang WC, Kuo HC. IL-31 associated with coronary artery lesion formation in Kawasaki disease. PLoS One 2014;9:e105195.
26. Dionne A, Ibrahim R, Gebhard C, et al. Coronary wall structural changes in patients with Kawasaki disease: new insights from optical coherence tomography (OCT). J Am Heart Assoc 2015;4:e001939.
27. Harris KC, Manouzi A, Fung AY, et al. Feasibility of optical coherence tomography in children with Kawasaki disease and pediatric heart transplant recipients. Circ Cardiovasc Imaging 2014;7:671-8.