



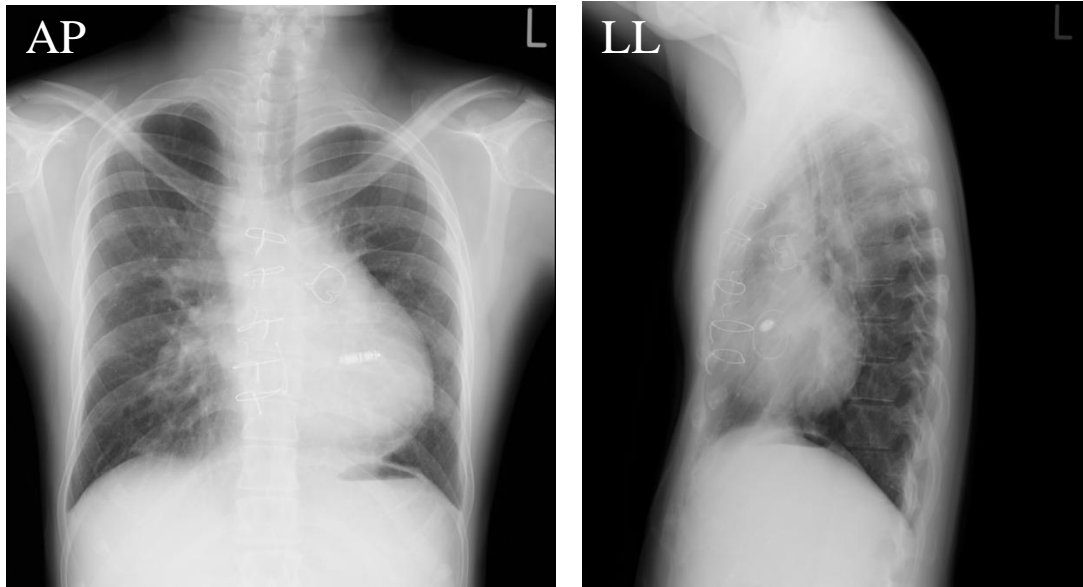
Title	A case report of pre-implantation feasibility test for combining leadless pacemaker and subcutaneous implantable cardioverter-defibrillator in adult congenital heart disease
Author(s)	Mima, Hibiki; Oka, Takafumi; Sera, Fusako et al.
Citation	Journal of Cardiology Cases. 2024, 30(6), p. 189-192
Version Type	AM
URL	<a href="https://hdl.handle.net/11094/98239">https://hdl.handle.net/11094/98239</a>
rights	© 2024. This manuscript version is made available under the CC-BY-NC-ND 4.0 license <a href="https://creativecommons.org/licenses/by-nc-nd/4.0/">https://creativecommons.org/licenses/by-nc-nd/4.0/</a>
Note	

*The University of Osaka Institutional Knowledge Archive : OUKA*

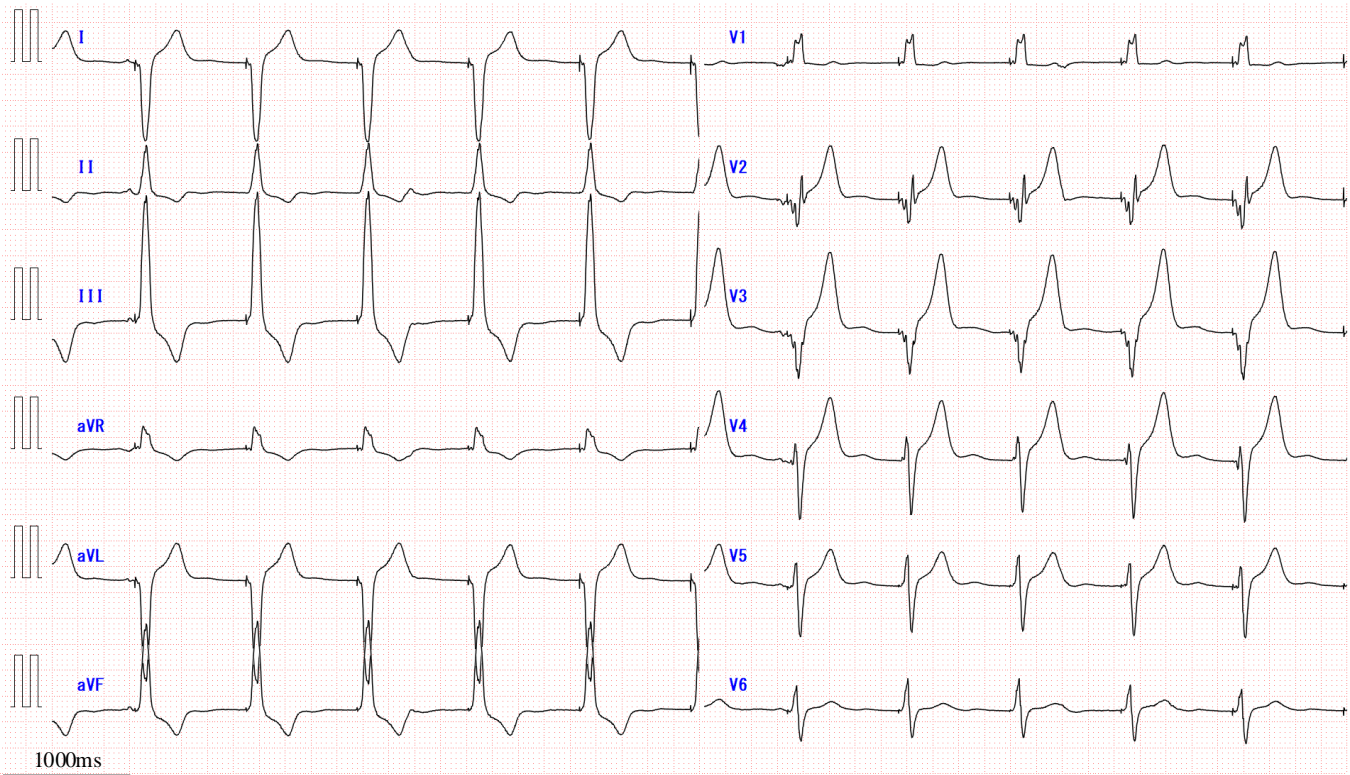
<https://ir.library.osaka-u.ac.jp/>

The University of Osaka

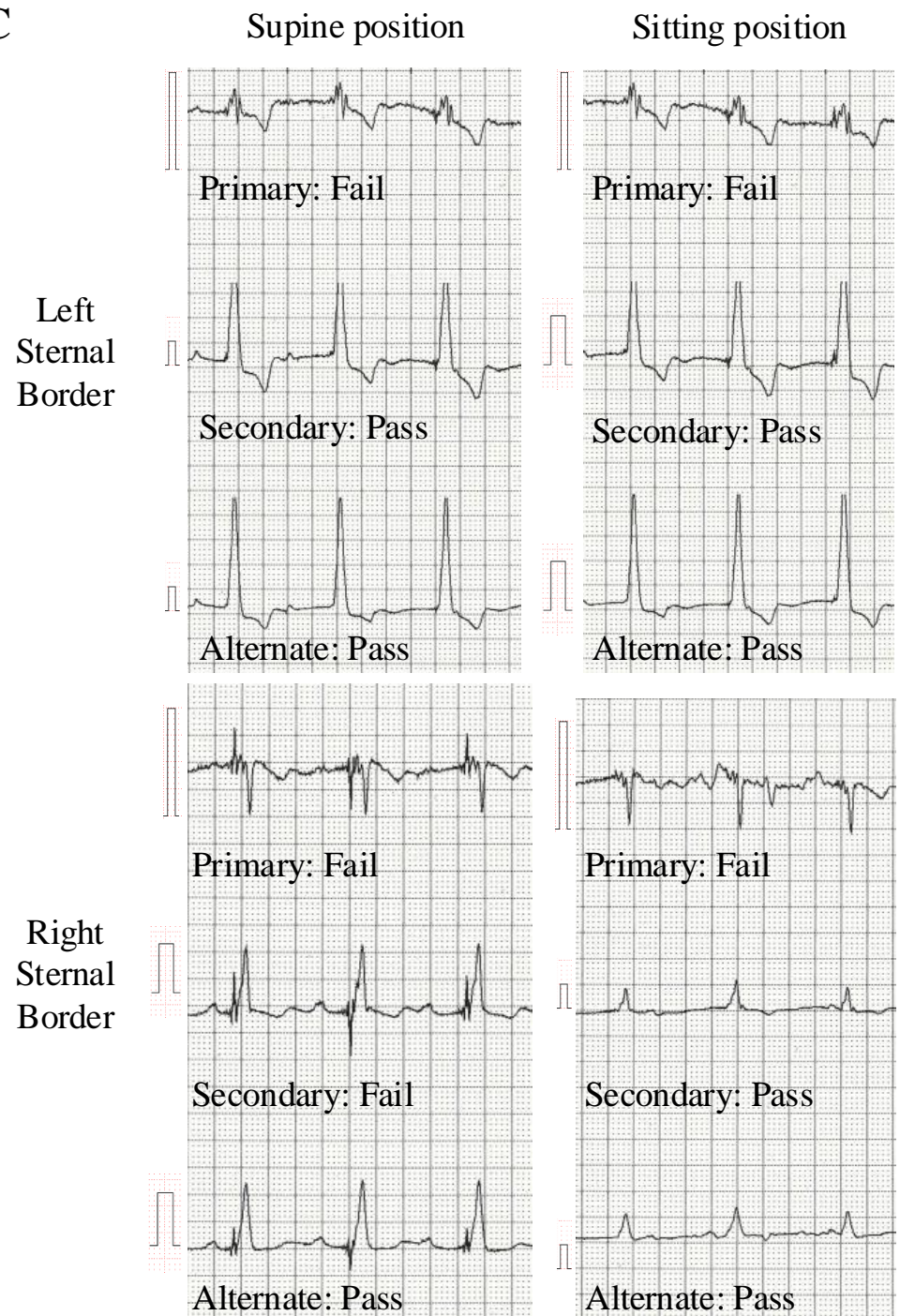
A



B



C



VVIR 70 ppm : QRS duration decreased to 140 msec